



# Management of Retinitis Pigmentosa via Platelet-Rich Plasma or Combination with Electromagnetic Stimulation: Retrospective Analysis of 1-Year Results

Umut Arslan · Emin Özmert

Received: February 20, 2020  
© Springer Healthcare Ltd., part of Springer Nature 2020

## ABSTRACT

**Purpose:** To investigate whether the natural progression rate of retinitis pigmentosa can be decreased by subtenon autologous platelet-rich plasma application alone or combination with retinal electromagnetic stimulation.

**Methods:** The study includes retrospective analysis of 60 patients with retinitis pigmentosa. Patients constitute three groups with similar demographic characteristics: the combined management group (group 1) consists of 20 patients with retinitis pigmentosa (40 eyes) who received combined retinal electromagnetic stimulation and subtenon platelet-rich plasma; the subtenon platelet-rich plasma-only group (group 2) consisted of 20 patients with retinitis pigmentosa (40 eyes); the natural course (control) group (group 3) consists of 20 patients with retinitis pigmentosa (40 eyes) who did not receive any treatment. Horizontal and vertical ellipsoid zone width, fundus perimetry

deviation index, and best corrected visual acuity changes were compared within and between groups after a 1-year follow-up period.

**Results:** Detected horizontal ellipsoid zone percentage changes were +1% in group 1, -2.85% in group 2, and -9.36% in group 3 ( $\Delta p 1 > 2 > 3$ ). Detected vertical ellipsoid zone percentage changes were +0.34% in group 1, -3.05% in group 2, and -9.09% in group 3 ( $\Delta p 1 > 2 > 3$ ). Detected fundus perimetry deviation index percentage changes were +0.05% in group 1, -2.68% in group 2, and -8.78% in group 3 ( $\Delta p 1 > 2 > 3$ ).

**Conclusion:** Platelet-rich plasma is a good source of growth factors, but its half-life is 4–6 months. Subtenon autologous platelet-rich plasma might more effectively slow down photoreceptor loss when repeated as booster injections and combined with retinal electromagnetic stimulation.

**Trial Registration:** ClinicalTrials.gov identifier, NCT04252534.

**Enhanced digital features** To view digital features for this article go to <https://doi.org/10.6084/m9.figshare.11994795>.

**Keywords:** Electromagnetic stimulation; Growth factors; Iontophoresis; Magnovision; Ophthalmology; Platelet-rich plasma; Retinitis pigmentosa

U. Arslan (✉)  
Ankara University Technopolis, Ankara, Turkey  
e-mail: drumutarслан@hotmail.com;  
bioretina.net@gmail.com

E. Özmert  
Department of Ophthalmology, Faculty of  
Medicine, Ankara University, Ankara, Turkey

## Key Summary Points

### Why carry out this study?

To investigate whether the natural progression rate of retinitis pigmentosa can be decreased by subtenon autologous platelet-rich plasma application alone or combination with retinal electromagnetic stimulation.

The retina pigment epithelium is the unit center where the synthesized peptide growth factors (GFs) regulate photochemical reactions.

The growth factors, peptides, and fragments required for these functions are encoded by over 260 genes in retinal pigment epithelium (RPE). Mutations in any of these genes leads to progressive vision loss and progressive degeneration of the sensorial unit.

This research attempts to answer the following question: is it possible for the growth factors applied into the subtenon region to reach the suprachoroidal area through the scleral pores and stop apoptosis or reactivate the photoreceptors in dormant phase?

The hypothesis is based on the fact that repetitive electromagnetic stimulation (rEMS) increases the affinity and synthesis of Trk growth factor receptors on neural tissues. rEMS also provides an electromagnetic iontophoresis effect by changing the electrical charges of the scleral pores and the peptides.

### What was learned from the study?

The results of the study confirmed our hypothesis without any adverse effect.

The ellipsoid zone width and visual field remain statistically significantly stable with combined treatment of electromagnetic stimulation and platelet-rich plasma when compared with control group at 1-year follow-up.

## INTRODUCTION

Retinitis pigmentosa (RP) is a progressive outer retinal degeneration resulting from any of the 260 genetic mutations found in the photoreceptor (PR) or retinal pigment epithelium (RPE) [1]. The progression rate and findings of the disease are heterogeneous according to genetic mutation and heredity type. The initial symptom of the disease is usually night blindness (nyctalopia) beginning in childhood or adolescence. Narrowing of the visual field and legal blindness develops as the disease progresses [2–4]. If low grade inflammation is added, then the disease is complicated by cataracts, an epiretinal membrane, and macular edema [5]. In the fundus examination, the appearance of midperipheral bone spicule pigmentation is usually sufficient for diagnosis [1]. Developments in spectral domain optical coherence tomography (SD-OCT) enable detailed imaging of the sensorial retina and the ellipsoid zone. Ellipsoid zone (EZ) is an OCT image of the inner and outer segments of photoreceptor cells. Loss of EZ is the gold standard in the diagnosis and follow-up of RP [6, 7]. Visual field (VF) monitoring and electroretinography (ERG) are indirect signs of EZ loss and correlated with EZ width (EZW) [6]. Mutations in PR or RPE disrupt the synthesis of some vital peptides and growth factors for photoreceptors [1].

Autologous platelet-rich plasma (aPRP) is a good source of growth factors. Platelets have more than 30 growth factors and cytokines in  $\alpha$ -granules. These peptides regulate the energy cycle at the cellular level. They also control local capillary blood flow, neurogenesis, and cellular metabolism [8, 9]. Subtenon aPRP application in the management of patients with RP has been shown to be clinically effective [10].

Repetitive electromagnetic stimulation (rEMS) increases binding affinity and the synthesis of growth factor receptors on neural tissues [11–14]. It provides electromagnetic iontophoresis by changing the electrical charges of scleral pores and tyrosine kinase receptors (Trk) [15–17]. rEMS forms hyperpolarization–depolarization waves in neurons, thereby

increasing neurotransmission and capillary blood flow [18]. Trk receptors are commonly found around limbus, extraocular muscle insertions, and the optic nerve [19]. Molecules smaller than 75 kDa can passively move from the sclera to the suprachoroidal space. Electrical or electromagnetic iontophoresis is required for molecules larger than 75 kDa such as brain-derived neurotrophic factor (BDNF) and insulin-like growth factor (IGF) to pass through the sclera into the subretinal space [15–17]. The clinical efficacy of rEMS alone or in combination with subtenon aPRP has also been shown [11].

The aim of this study is to investigate whether the natural progression rate of RP can be decreased by subtenon aPRP application alone or combination with rEMS. Ethics committee approval for the transcranial electromagnetic stimulation study was obtained from the Ankara University Faculty of Medicine Clinical Research Ethics Committee (17-1177-18). This committee had already approved the GFs work (19-1293-18). The study was performed in accordance with the tenets of the 2013 Declaration of Helsinki. Written informed consent was obtained from the patients prior to enrollment.

## METHODS

The study includes retrospective analysis of 60 patients with RP who were followed up at Ankara University Faculty of Medicine between 2017 and 2019. The best corrected visual acuity (BCVA) was recorded as letters on the Early Treatment Diabetic Retinopathy Study (ETDRS) chart (Topcon CC 100 XP, Japan). The ellipsoid zone width (EZW) shows healthy photoreceptors and was measured horizontally and vertically on cross-sectional structural SD-OCT (RTVue XR “Avanti”, Optovue, Fremont, CA, USA). A manual segmentation program was used for the measurement of EZW. Fundus perimetry deviation index (FPDI) records were examined in the 24/2 visual field of computerized perimetry records (Compass, CenterVue, Padova, Italy). The FPDI offers data explaining how many of the 100 flashing points can be

seen correctly by the patient and what percentage of the visual field can be seen.

Patients with RP were included in this study if they satisfied all of the following criteria: BCVA from 50 to 110 ETDRS letters, any phenotypic variation of RP, 18 years of age or older. Patients with RP were excluded from the study if they satisfied any of the following criteria: the presence of dense cataracts or the habit of smoking. The retrospective study was designed as comparative and open label. The 60 patients with RP constitute three groups with similar demographic characteristics:

- Group 1 The combined management group consists of 20 patients with RP (40 eyes) who received combined rEMS and aPRP. The rEMS was applied with a custom-designed helmet for 30 min just before the subtenon aPRP injection. These combined applications were repeated three times a month with a 2-week interval (loading dose). Then, two additional booster doses were applied with 6-month intervals. The course of the disease was evaluated by comparing the BCVA, EZW, and FPDI parameters recorded before the first application and within 3 months after the last application.
- Group 2 The aPRP-only group consisted of 20 patients with RP (40 eyes) who received only subtenon aPRP injections. The aPRP applications were repeated three times a month with a 2-week interval (loading dose). Then, two additional booster doses were applied with 6-month intervals. The course of the disease was evaluated by comparing the BCVA, EZW, and FPDI parameters recorded before the first application and within 3 months after the last application.
- Group 3 The natural course (control) group consists of 20 patients with RP (40 eyes) who did not receive any treatment and were followed. The natural course of the disease was

evaluated by comparing the BCVA, EZW, and FPDI parameters recorded at the beginning and at the end of the first year.

### Preparation of Autologous PRP and Its Application

A 20-ml aliquot of blood was taken from the antecubital veins of the patients. It was transferred sterile to two 10-ml citrated PRP tubes (T-LAB PRP Kit, T-Biyoteknoloji, Bursa, Turkey). The plasma was separated in a refrigerated centrifuge (1200 NF Nüve, Nüve Technology Laboratory, Ankara, Turkey) at + 4.0 °C for 8 min at 2500 rpm centrifugation. The bottom 1/3 of the upper plasma was drawn into a 2.5-ml sterile syringe as a section rich in growth factors. The 1.5 ml PRP solution was then injected into the subtenon space under topical anesthesia. The injections were made under sterile conditions at the upper-temporal quadrant with a 26-G needle tip.

### Retinal Repetitive Electromagnetic Stimulation (rEMS)

The rEMS helmet (Magnovision™, Bioretina Biotechnology, Ankara, Turkey) stimulated the retina and visual pathways with an electromagnetic field strength of 2000 milligauss, frequency of 42 Hz, and duration 30 min. The field was applied just before the PRP application. These values were previously determined to be effective for other clinical and preclinical studies.

The primary outcome measurements are the horizontal and vertical ellipsoid zone widths that directly show the structural changes in the photoreceptors. The secondary outcome measure is a change in micrometry FPDI values.

### Statistical Analysis of Data

Descriptive statistics are presented with frequency, percentage, mean, and standard deviation values. A paired *t* test was used to examine whether the pre- and post-measurement values

are different within groups. A Sidak binary comparison test examined the measurement difference between groups. An analysis of variance (ANOVA) test was performed to examine whether the groups are different by age. Here, *p* values less than 0.05 were considered statistically significant ( $\alpha = 0.05$ ). Analyses were made with SPSS 22.0 package program. The effect of interventional procedures on the natural course of retinitis pigmentosa was evaluated by comparing quantitative data from groups 1, 2, and 3.

## RESULTS

The mean age was 33.0 (22–51 years) in group 1, 32.6 (20–56 years) in group 2, and 31.7 (20–57 years) in group 3. The mean follow-up time between the first measurements and the last measurements in all three groups was 13 months (12–15 months). There were no statistical differences between the groups in terms of age and follow-up times ( $p = 0.81$ ).

### Mean Horizontal Ellipsoid Zone Width (m-HEZW)

The m-HEZW in group 1 was 3.46 mm before combined management and 3.50 mm after the procedures. During the mean 13-month follow-up, this positive change was 1.0% on average ( $p = 0.10$ ). In group 2, the m-HEZW was 3.32 mm at the first measurement and 3.26 mm after the PRP injections. During the mean 13-month follow-up, the change was found to be – 2.9% on average ( $p = 0.01$ ). In group 3, the m-HEZW was 3.32 mm at the initial examination and 3.03 mm at the last examination. Over the 13-month follow-up, this negative change was found to be – 9.4% on average ( $p = 0.01$ ) (Tables 1, 2, 3, 4; Figs. 1, 2, 3).

### Mean Vertical Ellipsoid Zone Width (m-VEZW)

The m-VEZW was 3.32 mm in group 1 before the combined application and 3.33 mm after the procedures. During the mean 13-month

**Table 1** Demographic characteristics and follow-up parameters of group 1 (management with aPRP + rEMS)

Patient no.	Age	Sex	Eye	Horizontal EZW			Vertical EZW			Visual field FPD1			BCVA	
				Before	After	%Difference	Before	After	%Difference	Before	After	Difference	Before	After
1	29	F	R	3.56	3.83	+ 7.6	4.62	4.84	+ 4.8	45	52	+ 7	110	110
			L	4.21	4.34	+ 3.1	3.36	3.41	+ 1.5	43	45	+ 2	110	110
2	37	M	R	6.87	6.90	+ 0.4	6.74	6.79	+ 0.7	57	60	+ 3	110	110
			L	3.97	4.14	+ 4.2	2.57	2.74	+ 6.6	57	60	+ 3	110	110
3	45	F	R	2.58	2.84	+ 10.1	1.90	2.06	+ 8.4	39	42	+ 3	100	100
			L	2.32	3.02	+ 30.2	2.17	2.30	+ 6.0	37	43	+ 6	100	100
4	38	M	R	3.43	3.43	0	2.52	2.70	+ 7.1	26	27	+ 1	100	100
			L	3.64	3.65	+ 0.3	2.75	2.82	+ 2.5	28	29	+ 1	100	100
5	32	M	R	4.01	4.00	- 0.3	3.92	3.89	- 0.8	48	46	- 2	110	110
			L	3.96	3.90	- 1.5	3.88	3.82	- 1.5	44	43	- 1	100	100
6	36	F	R	4.87	4.87	0	4.71	4.70	- 0.2	49	49	0	110	110
			L	4.91	4.90	- 0.2	4.70	4.68	- 0.4	50	49	- 1	110	110
7	38	F	R	7.01	7.16	+ 2.1	7.10	7.12	+ 0.3	65	67	+ 2	110	110
			L	7.03	7.20	+ 2.4	7.13	7.21	+ 1.1	66	70	+ 4	110	110
8	27	M	R	2.21	2.20	- 0.5	2.17	2.15	- 0.9	38	36	- 2	89	80
			L	2.17	2.16	- 0.5	2.14	2.12	- 0.9	37	36	- 1	75	75
9	24	F	R	2.76	2.71	- 2.0	2.74	2.71	- 1.1	41	39	- 2	85	85
			L	2.66	2.63	- 1.1	2.69	2.61	- 2.6	40	39	- 1	85	85
10	28	F	R	2.61	2.60	- 0.4	2.70	2.70	0	27	27	0	80	80
			L	2.59	2.58	- 1.2	2.34	2.31	- 1.3	26	25	- 1	80	80
11	31	M	R	2.43	2.40	- 1.2	2.38	2.37	- 0.4	32	30	- 2	75	75
			L	2.40	2.40	0	2.38	2.37	- 0.4	30	30	0	75	75

Table 1 continued

Patient no.	Age	Sex	Eye	Horizontal EZW			Vertical EZW			Visual field FPD			BCVA	
				Before	After	%Difference	Before	After	%Difference	Before	After	Difference	Before	After
12	26	M	R	1.24	1.20	- 3.2	1.36	1.29	- 5.1	38	36	- 2	70	70
			L	1.19	1.16	- 2.5	1.20	1.18	- 1.7	35	33	- 2	70	70
13	20	F	R	6.71	6.69	- 0.3	6.70	6.68	- 0.3	76	74	- 2	110	100
			L	6.56	6.56	0	6.49	6.48	- 0.2	72	71	- 1	110	100
14	23	F	R	1.64	1.64	0	1.49	1.49	0	25	25	0	70	70
			L	1.66	1.65	- 0.6	1.38	1.37	- 0.7	27	26	- 1	70	70
15	49	M	R	5.84	5.78	- 1.1	5.91	5.89	- 0.3	76	74	- 2	110	110
			L	5.77	5.73	- 0.7	5.79	5.76	- 0.5	72	70	- 2	110	110
16	51	F	R	4.98	4.96	- 0.4	3.98	3.96	- 0.5	68	67	- 1	110	110
			L	4.78	4.76	- 0.4	4.00	3.98	- 0.5	66	64	- 2	110	110
17	30	M	R	2.63	2.60	- 1.1	2.46	2.44	- 0.8	39	37	- 2	85	85
			L	1.99	1.94	- 2.5	1.87	1.84	- 1.6	34	32	- 2	80	80
18	47	F	R	0.95	0.95	0	1.02	1.00	- 2.0	20	20	0	50	50
			L	1.01	0.99	- 2.0	1.12	1.10	- 1.8	22	21	- 1	65	65
19	22	F	R	2.36	2.33	- 1.3	1.98	1.96	- 1.0	36	34	- 2	89	89
			L	1.90	1.88	- 1.1	1.87	1.85	- 1.1	32	31	- 1	75	75
20	25	F	R	1.56	1.53	- 1.9	1.77	1.74	- 1.7	30	29	- 1	65	65
			L	1.74	1.71	- 1.7	1.82	1.79	- 1.7	30	29	- 1	65	65

*aPRP* autologous platelet-rich plasma, *rEMS* repetitive electromagnetic stimulation, *EZW* ellipsoid zone width (mm), *FPDI* fundus perimetry deviation index (%), *BCVA* best corrected visual acuity

**Table 2** Demographic characteristics and follow-up parameters of group 2 (management with only aPRP)

Patient no.	Age	Sex	Eye	Horizontal EZW			Vertical EZW			Visual field FFDI			BCVA	
				Before	After	%Difference	Before	After	%Difference	Before	After	Difference	Before	After
1	39	M	R	2.89	2.94	+ 1.7	2.10	2.21	+ 5.2	26	28	+ 2	80	80
			L	2.23	2.51	+ 12.0	2.29	2.32	+ 1.3	24	28	+ 4	80	80
2	37	M	R	6.36	6.47	+ 1.7	6.32	6.47	+ 2.4	64	64	0	110	110
			L	7.03	7.21	+ 2.4	7.13	7.20	+ 1.0	71	72	+ 1	110	110
3	47	F	R	7.77	8.30	+ 6.8	7.47	7.65	+ 2.4	75	77	+ 2	110	110
			L	7.95	7.97	+ 0.3	6.91	7.09	+ 1.4	76	77	+ 1	110	110
4	28	F	R	4.87	4.62	- 5.1	3.82	3.56	- 6.9	45	40	- 5	100	100
			L	4.92	4.84	- 1.6	3.73	3.71	- 0.5	43	40	- 3	100	100
5	26	F	R	3.76	3.61	- 4.0	2.63	2.58	- 1.9	64	60	- 4	100	100
			L	4.14	3.97	- 4.1	2.59	2.57	- 0.8	63	60	- 3	100	100
6	40	M	R	2.77	2.63	- 5.1	2.37	2.18	- 8.0	42	36	- 6	75	70
			L	2.48	2.32	- 6.5	2.16	2.10	- 2.8	35	30	- 5	75	70
7	30	F	R	1.98	1.89	- 5.5	1.92	1.83	- 4.7	32	28	- 4	65	65
			L	2.01	1.89	- 5.9	1.97	1.87	- 5.1	33	28	- 5	65	65
8	20	F	R	2.77	2.64	- 4.7	1.96	1.84	- 6.1	60	54	- 6	80	75
			L	3.00	2.87	- 4.3	2.08	1.97	- 5.3	59	55	- 4	80	75
9	23	M	R	3.89	3.70	- 4.9	3.71	3.46	- 6.7	53	50	- 3	89	89
			L	3.76	3.41	- 9.3	3.63	3.42	- 5.8	50	45	- 5	85	80
10	28	M	R	2.71	2.60	- 4.0	2.84	2.70	- 4.9	41	38	- 3	89	89
			L	2.96	2.81	- 5.1	2.73	2.59	- 5.1	41	38	- 3	89	89
11	29	F	R	3.73	3.61	- 3.2	3.37	3.23	- 4.2	55	52	- 3	95	95
			L	3.90	3.77	- 3.3	4.11	3.89	- 5.4	60	56	- 4	95	95

Table 2 continued

Patient no.	Age	Sex	Eye	Horizontal EZW			Vertical EZW			Visual field FPD			BCVA	
				Before	After	%Difference	Before	After	%Difference	Before	After	Difference	Before	After
12	24	F	R	2.86	2.71	- 5.2	2.77	2.61	- 5.8	40	36	- 4	85	85
			L	2.76	2.63	- 4.7	2.65	2.50	- 5.7	40	36	- 4	85	85
13	50	F	R	2.22	2.09	- 5.9	2.86	2.72	- 4.9	44	39	- 5	100	100
			L	2.61	2.47	- 5.4	3.11	2.96	- 4.8	47	44	- 3	110	110
14	32	M	R	2.53	2.51	- 0.8	2.48	2.47	- 0.4	34	34	0	75	75
			L	2.50	2.49	- 0.4	2.48	2.47	- 0.4	33	33	0	75	75
15	56	F	R	5.08	4.96	- 2.4	4.98	4.86	- 2.4	70	67	- 3	110	110
			L	4.98	4.86	- 2.4	4.71	4.58	- 2.8	69	66	- 3	110	110
16	31	M	R	1.34	1.26	- 6.0	1.38	1.30	- 5.8	38	34	- 4	70	70
			L	1.29	1.21	- 6.2	1.30	1.23	- 5.4	36	32	- 4	70	70
17	23	F	R	2.33	2.24	- 3.9	2.00	1.96	- 2.0	35	32	- 3	89	89
			L	1.97	1.91	- 3.0	1.89	1.82	- 3.7	31	28	- 3	75	75
18	32	F	R	1.77	1.68	- 5.1	1.53	1.45	- 5.2	30	25	- 5	80	80
			L	1.54	1.49	- 3.2	1.70	1.62	- 4.7	27	24	- 3	74	74
19	28	M	R	1.88	1.80	- 4.3	1.88	1.81	- 3.7	48	44	- 4	85	85
			L	2.05	1.98	- 3.4	2.49	2.40	- 3.6	56	53	- 3	92	92
20	29	F	R	2.70	2.70	0	2.76	2.76	0	28	28	0	80	80
			L	2.69	2.69	0	2.64	2.64	0	27	27	0	80	80

*aPRP* autologous platelet-rich plasma, *rEMS* repetitive electromagnetic stimulation, *EZW* ellipsoid zone width (mm), *FPDI* fundus perimetry deviation index (%), *BCVA* best corrected visual acuity



**Table 3** Demographic characteristics and follow-up parameters of group 3 (natural course)

Patient no.	Age	Sex	Eye	Horizontal EZW			Vertical EZW			Visual field FPD1			BCVA	
				Before	After	%Difference	Before	After	%Difference	Before	After	Difference	Before	After
1	48	M	R	8.30	7.77	- 6.4	7.77	7.27	- 6.4	78	67	- 11	110	100
			L	8.30	7.95	- 4.2	7.97	7.09	- 11.1	73	64	- 9	110	110
2	50	M	R	2.12	1.78	- 12.5	2.76	2.50	- 9.4	46	34	- 12	100	95
			L	2.71	2.49	- 8.2	3.01	2.63	- 12.6	49	40	- 9	95	95
3	32	F	R	7.45	7.01	- 5.9	5.68	5.15	- 8.8	85	78	- 7	100	100
			L	8.24	7.80	- 5.3	7.98	7.00	- 12.2	88	80	- 8	100	100
4	29	F	R	3.73	3.10	- 16.8	2.87	2.70	- 6.9	72	63	- 9	95	95
			L	3.79	3.23	- 14.7	3.68	3.29	- 10.5	84	73	- 11	100	100
5	30	F	R	1.92	1.68	- 12.5	1.82	1.72	- 5.6	36	28	- 8	70	70
			L	1.60	1.50	- 6.3	1.55	1.39	- 10.3	32	25	- 7	70	70
6	46	M	R	3.11	2.78	- 10.6	3.50	3.02	- 13.7	55	46	- 9	110	100
			L	3.02	2.90	- 4.0	3.41	3.22	- 5.6	53	45	- 8	110	110
7	31	F	R	1.57	1.42	- 9.5	1.33	1.21	- 9.0	30	22	- 8	80	80
			L	1.34	1.21	- 9.7	1.63	1.51	- 7.3	27	19	- 8	74	74
8	27	F	R	1.80	1.65	- 8.3	1.78	1.60	- 10.1	48	39	- 9	85	85
			L	2.15	1.97	- 8.4	2.39	2.20	- 7.9	56	48	- 8	92	92
9	57	M	R	1.36	1.20	- 11.8	1.46	1.31	- 10.3	17	9	- 8	65	65
			L	1.12	0.98	- 12.5	1.24	1.10	- 11.3	9	4	- 5	50	50
10	22	M	R	5.75	5.16	- 10.3	5.01	4.54	- 9.4	51	40	- 11	110	110
			L	5.69	5.13	- 9.8	5.22	4.84	- 7.3	50	41	- 9	110	110
11	26	F	R	2.40	2.10	- 12.5	2.40	2.12	- 11.6	55	39	- 11	74	74
			L	2.70	2.50	- 7.4	2.60	2.35	- 9.6	59	47	- 12	80	74

Table 3 continued

Patient no.	Age	Sex	Eye	Horizontal EZW			Vertical EZW			Visual field FPD			BCVA	
				Before	After	%Difference	Before	After	%Difference	Before	After	Difference	Before	After
12	30	F	R	1.90	1.80	- 5.2	1.80	1.70	- 5.5	49	43	- 6	80	80
			L	2.00	1.80	- 10.0	1.90	1.70	- 10.5	52	43	- 9	85	80
13	27	F	R	4.09	3.67	- 10.3	3.44	3.07	- 10.8	68	56	- 12	89	89
			L	4.09	3.79	- 7.3	3.76	3.68	- 2.2	69	63	- 6	89	89
14	29	M	R	3.71	3.39	- 8.6	3.30	3.00	- 9.1	56	48	- 8	95	95
			L	4.01	3.57	- 11.0	4.14	3.59	- 13.3	61	51	- 10	100	100
15	20	F	R	3.60	3.40	- 5.5	4.60	4.30	- 6.5	71	65	- 6	95	95
			L	4.84	4.60	- 4.9	3.70	3.50	- 5.4	72	67	- 4	95	95
16	23	M	R	3.45	3.09	- 10.4	3.74	3.34	- 10.7	52	44	- 8	100	100
			L	3.27	2.97	- 9.2	3.61	3.30	- 8.6	50	40	- 10	100	95
17	25	F	R	1.65	1.50	- 9.1	2.08	1.93	- 7.2	45	37	- 8	74	74
			L	1.10	0.97	- 11.8	1.83	1.71	- 6.5	40	33	- 7	70	70
18	20	F	R	1.70	1.55	- 8.8	1.90	1.75	- 7.9	50	41	- 9	80	80
			L	2.10	1.90	- 9.5	3.20	3.00	- 6.3	58	51	- 7	85	85
19	33	M	R	3.43	3.06	- 10.8	3.19	2.78	- 12.9	57	47	- 10	100	100
			L	3.40	3.01	- 11.5	3.33	2.97	- 10.8	58	47	- 11	100	100
20	28	F	R	2.16	1.90	- 12.0	2.14	1.92	- 10.2	56	45	- 11	74	74
			L	2.13	1.90	- 10.8	2.26	1.98	- 12.3	55	43	- 12	74	74

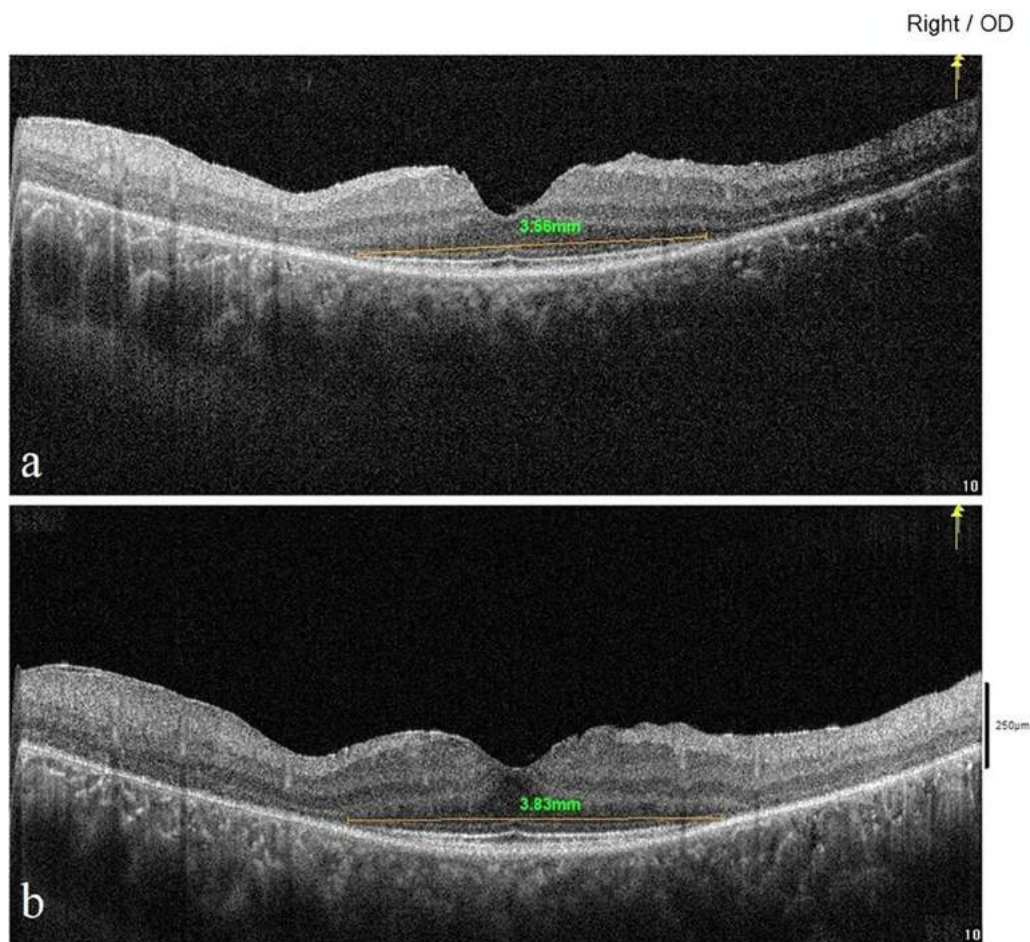
*aPRP* autologous platelet-rich plasma, *rEMS* repetitive electromagnetic stimulation, *EZW* ellipsoid zone width (mm), *FPDI* fundus perimetry deviation index (%), *BCVA* best corrected visual acuity

**Table 4** Comparison of assessment parameters before the treatments and at the end of the 1-year follow-up period between three groups

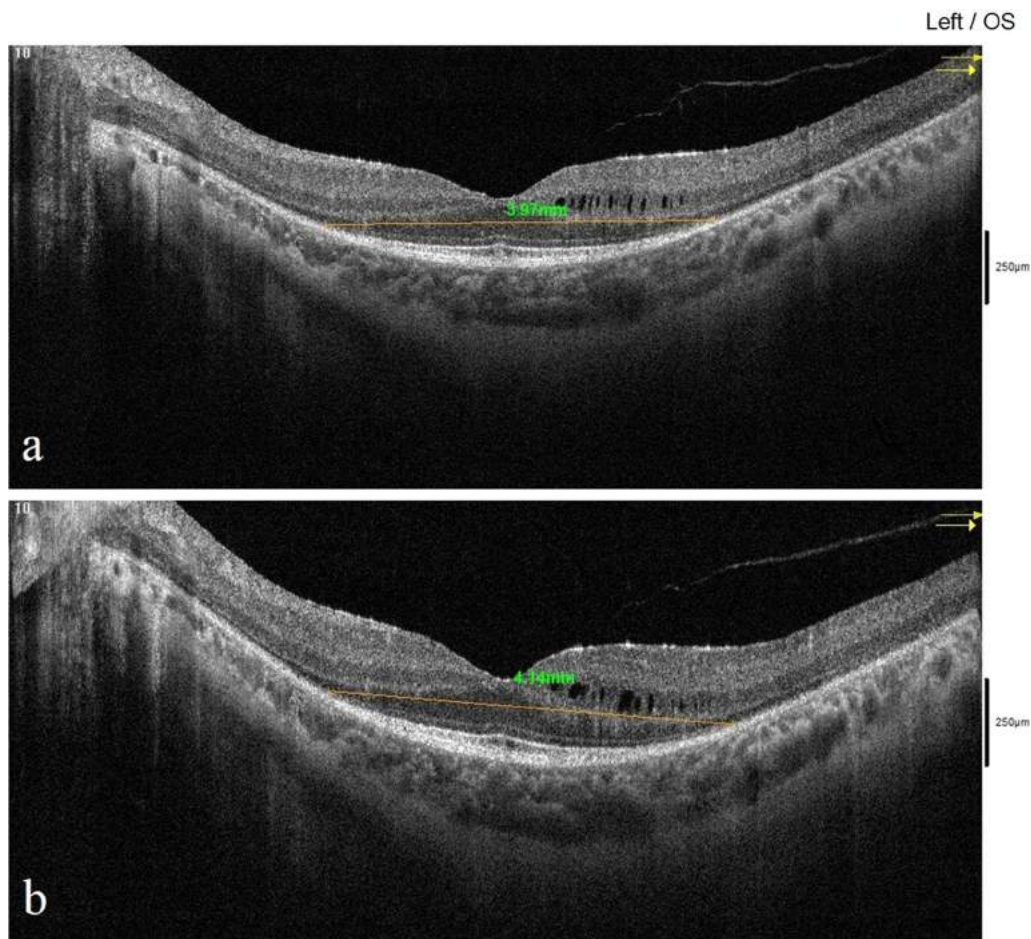
Group 1 (n = 40) X ± SD	Group 2 (n = 40) X ± SD	Group 3 (n = 40) X ± SD	p	Difference**
Horizontal EZW %difference				
1 ± 2.4	- 2.85 ± 2.8	- 9.36 ± 2.8	0.01*	1 > 2 > 3
Vertical EZW %difference				
0.34 ± 2.8	- 3.05 ± 2.7	- 9.09 ± 2.6	0.01*	1 > 2 > 3
Visual field FPDJ difference				
0.05 ± 2.5	- 2.68 ± 2.3	- 8.78 ± 2.0	0.01*	1 > 2 > 3

aPRP autologous platelet-rich plasma, rEMS repetitive electromagnetic stimulation, EZW ellipsoid zone width (mm), FPDJ fundus perimetry deviation index (%), BCVA best corrected visual acuity

\*\*Sidak binary comparison test



**Fig. 1** Horizontal EZWs of a patient with retinitis pigmentosa receiving aPRP + rEMS (Table 1, patient no. 1). **a** Before treatment, 3.56 mm. **b** The 13th month of follow-up post-treatment, 3.83 mm



**Fig. 2** Horizontal EZWs of a patient with retinitis pigmentosa receiving aPRP + rEMS (Table 1, patient no. 2). **a** Before treatment, 3.97 mm. **b** The 13th month of follow-up post-treatment, 4.14 mm

follow-up, the change was 0.3% on average ( $p = 0.19$ ). In group 2, the m-VEZW was 3.09 mm at the first measurement and 3.02 mm after PRP injections. The change was  $-3.1\%$  on average during the mean 13-month follow-up ( $p = 0.01$ ). In group 3, the m-VEZW was 3.27 mm at the initial examination and 2.97 mm at the last examination. The change was found to be  $-9.1\%$  on average during the mean 13-month follow-up ( $p = 0.01$ ) (Tables 1, 2, 3, 4; Figs. 4, 5).

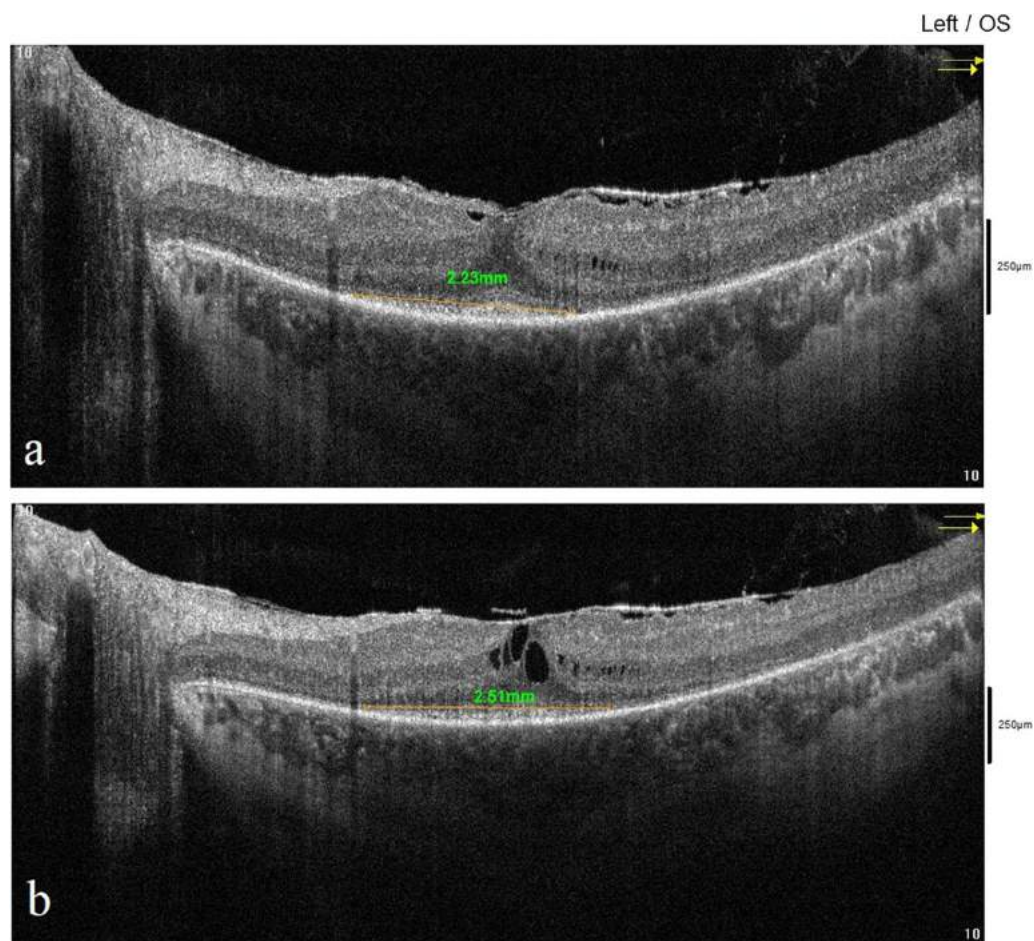
#### Mean Fundus Perimetry Deviation Index (m-FPDI)

This value was 43.45% in group 1 before PRP combined with rEMS and 43.50% after the

procedures. The mean change was 0.05% on average during the 13-month follow-up ( $p = 0.90$ ). In group 2, the m-FPDI was 46.13% at the first measurement and 43.45% after PRP injections. The change was  $-2.68\%$  on average during the mean 13-month follow-up ( $p = 0.01$ ). In group 3, the m-FPDI was 54.30% at the initial examination and 45.38% at the last examination. The change was  $-8.78\%$  on average during the mean 13-month follow-up ( $p = 0.01$ ) (Tables 1, 2, 3, 4; Figs. 6, 7, 8, 9, 10).

#### Mean Best Corrected Visual Acuity (m-BCVA)

Group 1 could identify 91.6 letters before PRP combined with rEMS applications and 92.3



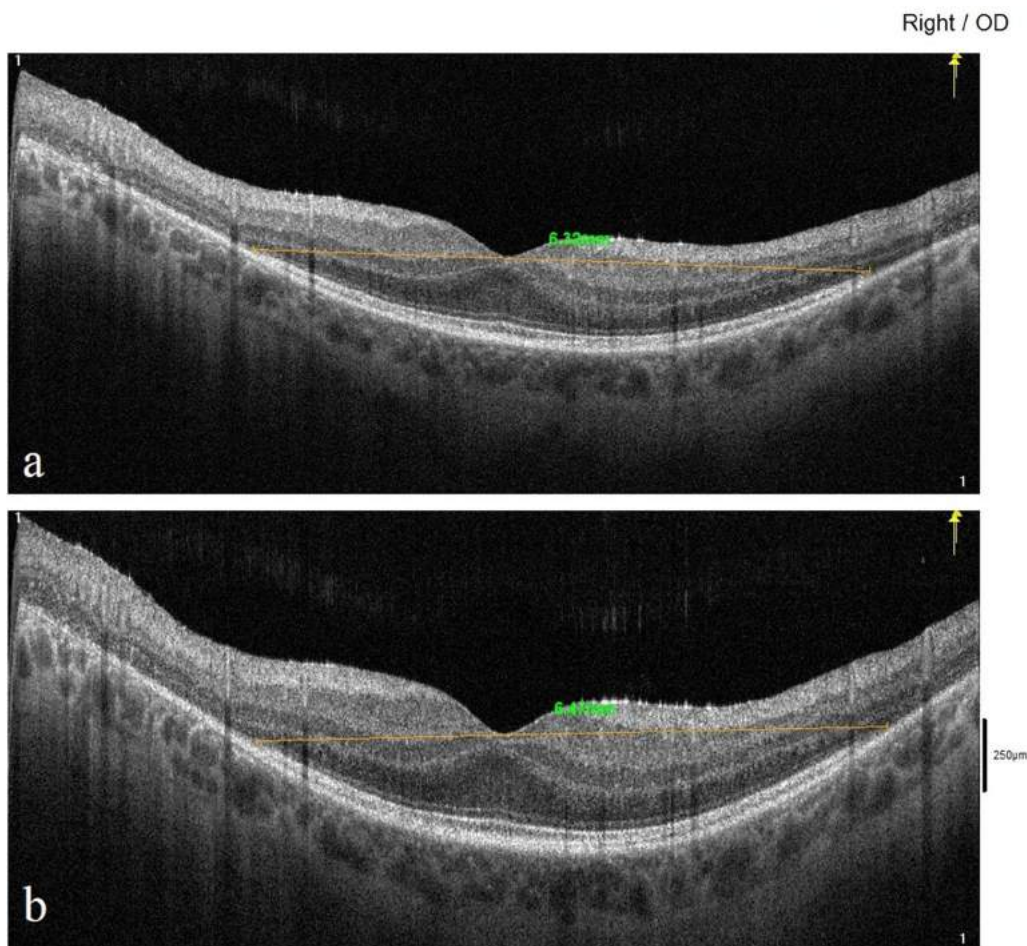
**Fig. 3** Horizontal EZWs of a patient with retinitis pigmentosa receiving only aPRP (Table 2, patient no. 1). **a** Before treatment, 2.23 mm. **b** The 13th month of follow-up post-treatment, 2.51 mm

letters after the procedure. During the mean 13-month follow-up, the change was found to be an average of 0.7 letters ( $p = 0.08$ ). Group 2 had an m-BCVA of 88.2 letters at baseline and 87.6 letters after PRP injections. The change was  $-0.6$  letters on average ( $p = 0.07$ ) during the mean 13-month follow-up. Group 3 had an m-BCVA score of 89.8 letters at the initial examination and 88.4 letters at the end. The change was found to be an average of  $-1.4$  letters during the mean 13-month follow-up ( $p = 0.02$ ).

When groups 1, 2, and 3 were compared by the Sidak test according to the HEZW, VEZW, and FPDI changes, the combined application of rEMS and subtenon aPRP significantly increases the three assessment parameters (Table 4).

## DISCUSSION

There are currently over 260 different genetic mutations known to cause retinitis pigmentosa. Genetic inheritance can be autosomal dominant (AD), autosomal recessive (AR), X-linked, mitochondrial, mosaicism, or sporadic patterns [1]. Thus, the prognosis is usually quite heterogeneous. Acquired factors such as nutrition, smoking, anemia, pregnancy, as well as long-term exposure to ultraviolet and blue light also affect the course of the disease [2–4]. Autosomal dominant inheritance shows the slowest progression with an average annual loss of 5% photoreceptors [20, 21]. X-linked inheritance shows the fastest progression with an average annual loss of 15% of photoreceptors [21, 22].

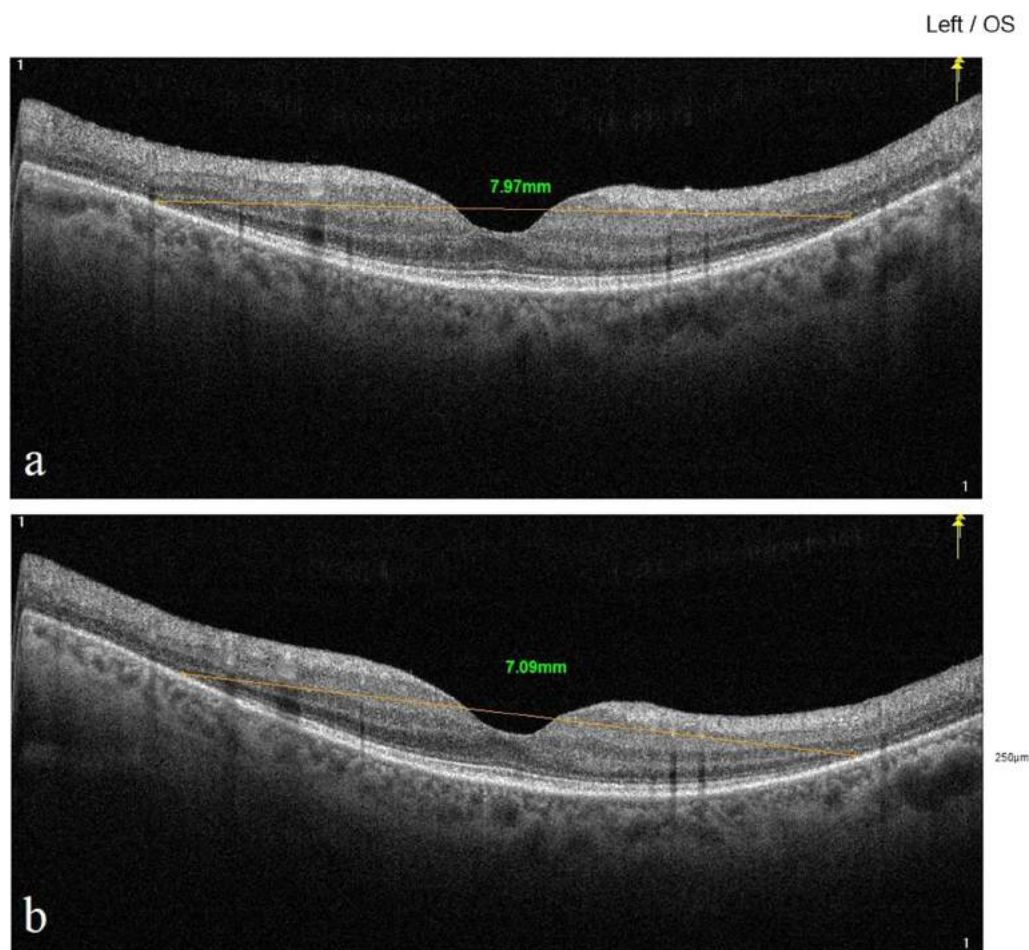


**Fig. 4** Vertical EZWs of a patient with retinitis pigmentosa receiving only aPRP (Table 2, patient no. 1). **a** Before treatment, 6.32 mm. **b** The 13th month of follow-up post-treatment, 6.47 mm

Knowledge about which genetic mutation affects the progression is increasing owing to widespread genetic testing. The annual progression rate of retinitis pigmentosa was reported to be 5% in *RHO* gene mutation that was inherited as AD, and 15% in *RPGR* gene mutation inherited as X-linked [20–22]. The photoreceptors have cilia tubule functions that provide the transport of opsin and rhodopsin and can be impaired by X-linked mutations—they can be distinguished by the presence of widespread lipofuscin deposits in the fundus examination. The ciliopathy gene mutations have threefold faster progression than non-ciliopathy mutations [23]. Retinitis pigmentosa progresses with an average of 10% annual photoreceptor loss when AD, AR, X-linked, and

mitochondrial inheritance patterns are collectively evaluated [6, 24, 25]. In our study, the annual photoreceptor loss rate was found to be 9.3% on average in the RP group without interventional procedures (group 3, natural course) similar to the literature.

The visual function begins with the photochemical conversion of light energy, which comes from the objects and focuses on the retina with conversion to electrical signals. Photochemical conversion occurs in the sensorial unit and microenvironment consisting of a choriocapillaris–retina pigment epithelium–photoreceptor trio. The retina pigment epithelium is the unit center where the synthesized peptide growth factors (GFs) regulate photochemical reactions. These include the

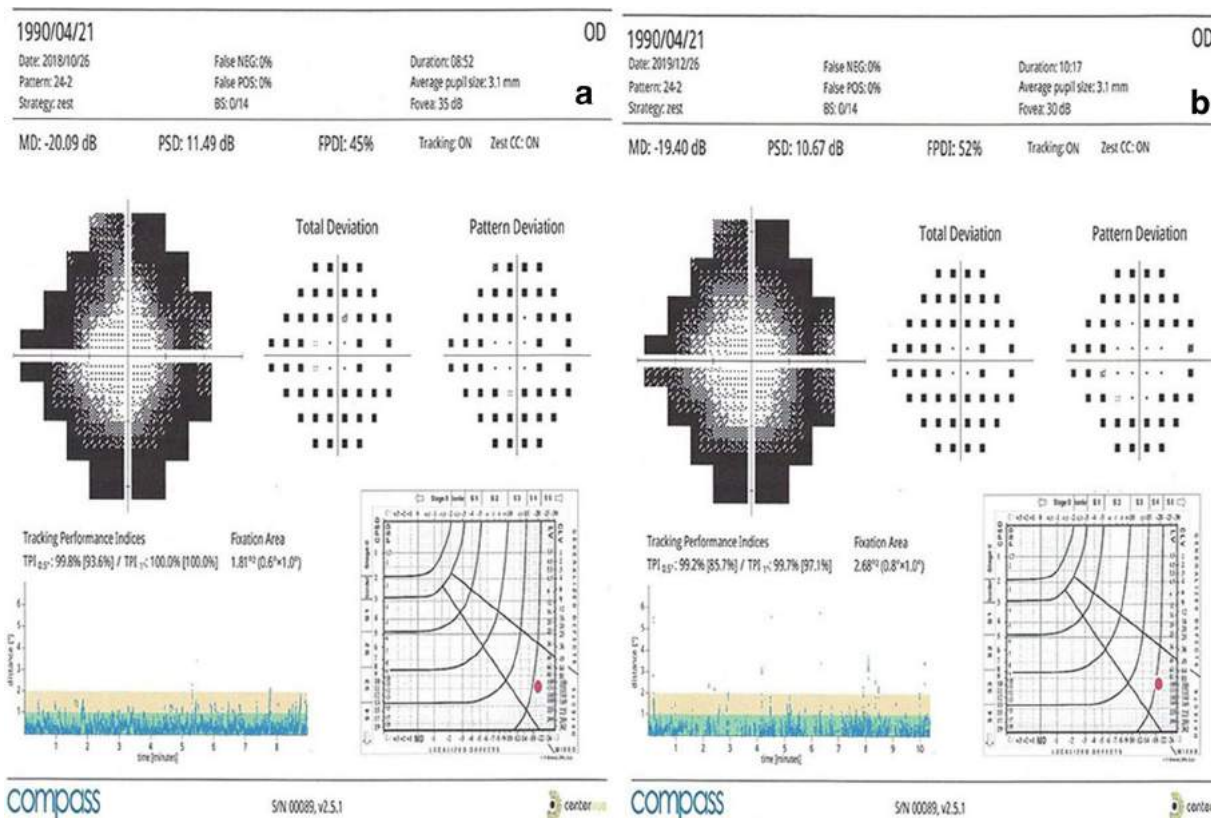


**Fig. 5** Vertical EZWs of a patient with retinitis pigmentosa, natural course (Table 3, patient no. 1). **a** Before treatment, 7.97 mm. **b** The 13th month of follow-up post-treatment, 7.09 mm

oxidative phosphorylation and energy cycle of glucose in the blood; transport of vitamin A, minerals, anions, cations, and necessary coenzymes; the synthesis of opsin–rhodopsin and necessary peptides in the visual cycle; and the removal of metabolic waste that occurs in RPE [26–29].

The growth factors, peptides, and fragments required for these functions are encoded by over 260 genes in RPE. Mutations in any of these genes leads to progressive vision loss and progressive degeneration of the sensorial unit [1]. In particular, mutations that affect the conversion of glucose to adenosine triphosphate (ATP) lead to a condition in photoreceptor cells called sleep mode or dormant phase [30, 31]. Cells in this state have more solid plasma—they are live

but metabolically inactive [32]. The photoreceptors in the dormant phase can be metabolically reactive if neurotrophins and GFs can be delivered the microenvironment of the sensorial unit [33]. Neurotrophins and GFs are key molecules in the cellular energy cycle [34]. Prolonged dormant phase or conditions impairing sensorial unit homeostasis eventually lead to apoptosis and cell loss [33]. RPE forms the outer blood–retinal barrier with its tight connections. Defects in the external blood retinal barrier due to apoptosis disrupt the immune-protected state in the retina and lead to low-density inflammation in the sensory unit. Neuroinflammation accelerates the apoptosis process and sensorial unit loss [5].



**Fig. 6** Visual field FPDIs changes of the retinitis pigmentosa patient receiving aPRP + rEMS (Table 1, patient no. 1). **a** Before treatment, 45%. **b** The 13th month of follow-up post-treatment, 52%

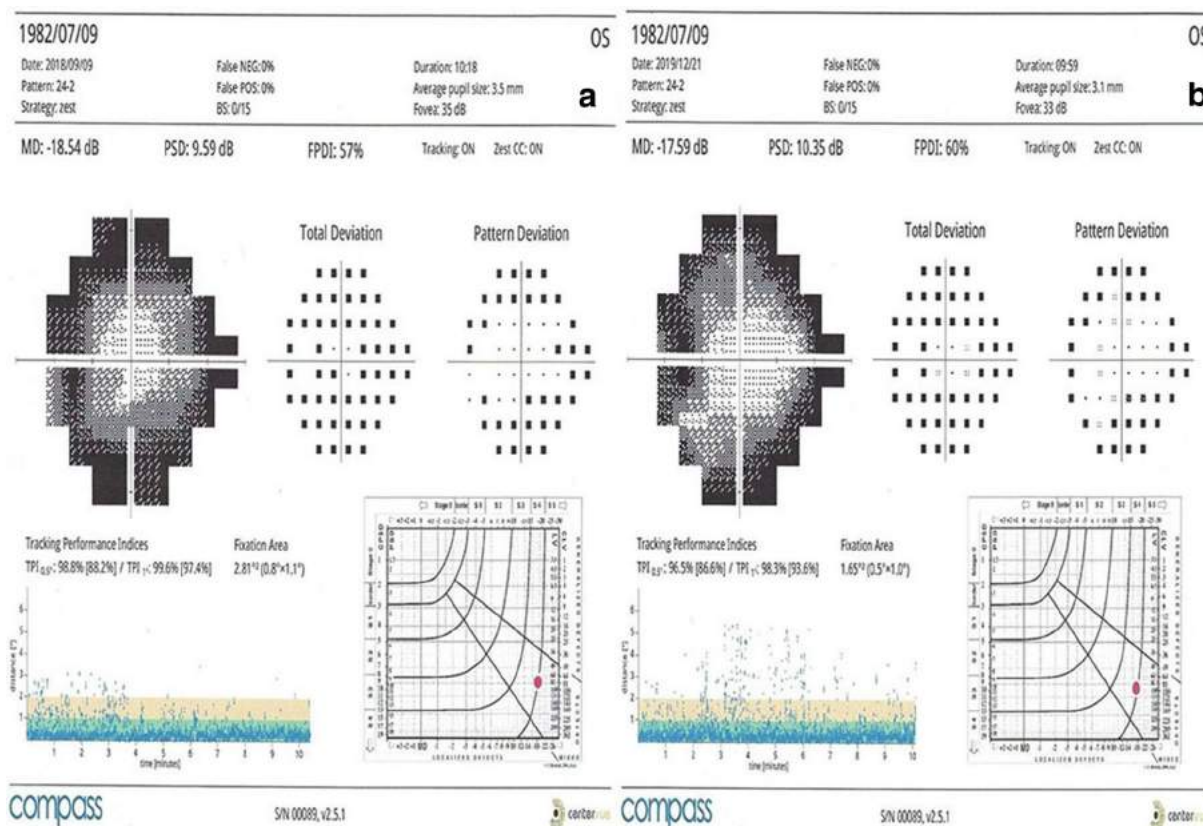
Platelet-rich plasma is a good source of growth factors. Platelets have more than 30 GFs and cytokines in  $\alpha$ -granules such as neurotrophic growth factor (NGF), neural factor (NF), BDNF, basic fibroblast growth factor (bFGF), IGF, transforming growth factor (TGF $\beta$ ), vascular endothelial growth factor (VEGF), platelet-derived growth factor (PDGF), etc. These peptides regulate the energy cycle at the cellular level, local capillary blood flow, neurogenesis, and cellular metabolism [8–10]. Anti-inflammatory effects of PRP are also associated with soluble cytokines [35].

Our previous clinical and prospective study showed that subtenon injection of aPRP significantly increased the visual functions [10, 11]. Clinical and preclinical studies showed that the half-life of GFs in tissue derived from PRP is 4–6 months [36–38]. Our clinical observations are similar. Here, we investigated the effects of three loading doses with a 2-week interval and

two boosters with 6-month interval of subtenon aPRP injections on photoreceptor loss (measured by EZW on SD-OCT) during the 1-year follow-up. The photoreceptor loss rates during the follow-up period were 9.3% in the natural course group (group 3) and 3% in the aPRP-only group (group 2). These results suggest that subtenon aPRP injection can decrease the photoreceptor loss rate by approximately threefold.

The growth factors applied into the subtenon region reach the suprachoroidal area through the scleral pores. GFs in the choroidal matrix reach the subretinal area through Trk receptors. Tyrosine kinase receptors are commonly found around the limbus, extraocular muscle insertions, and the optic nerve [19]. Molecules smaller than 75 kDa can pass through the sclera via passive transport to the suprachoroidal space [17]. BDNF and IGF are key growth factors in PRP and are larger than 75 kDa [9].



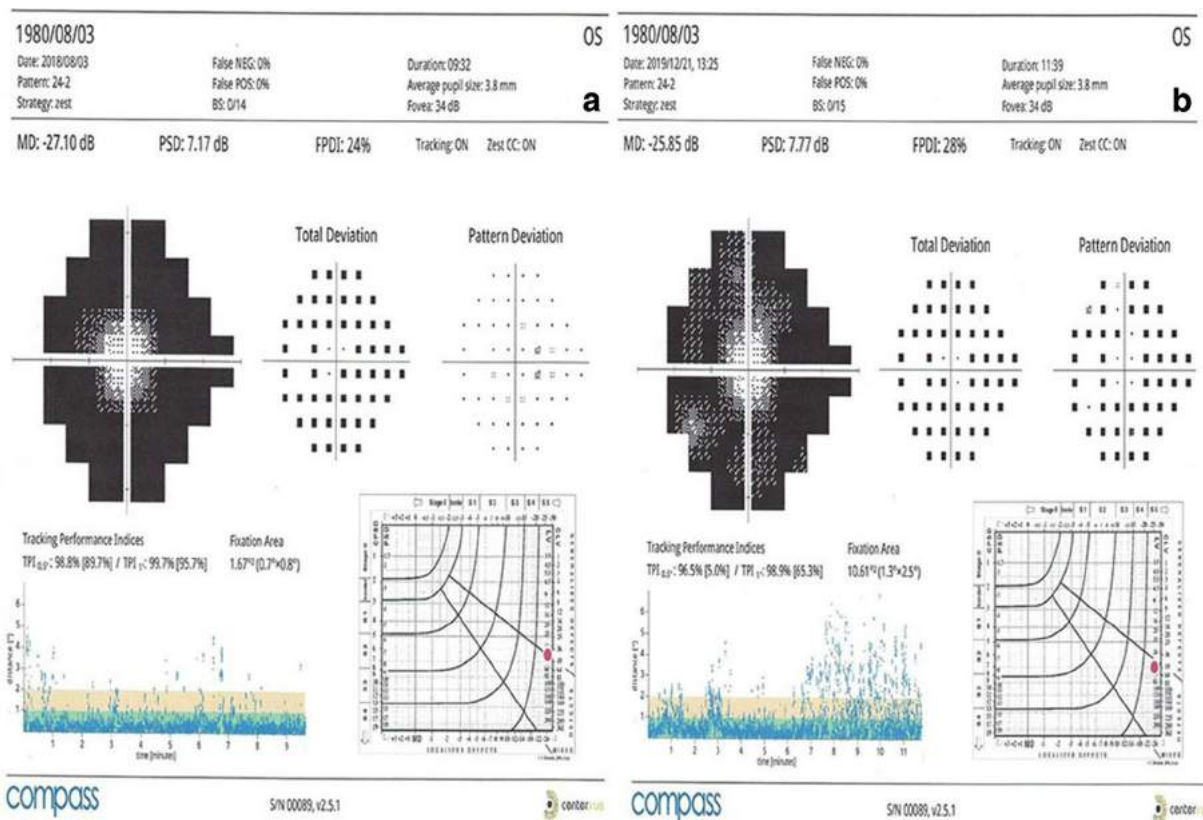


**Fig. 7** Visual field FPDIs changes of a patient with retinitis pigmentosa receiving aPRP + rEMS (Table 1, patient no. 2). **a** Before treatment, 57%. **b** The 13th month of follow-up post-treatment, 60%

Repetitive electromagnetic stimulation increases the affinity and synthesis of Trk growth factor receptors on neural tissues [11–14]. rEMS also provides electromagnetic iontophoresis effects by changing the electrical charges of the scleral pores and the peptides. Electrical or electromagnetic iontophoresis accelerates the passage of the large molecules such as BDNF and IGF through the sclera [15–17]. rEMS creates hyperpolarization–depolarization waves in neurons, which increases neurotransmission and capillary blood flow [18]. In group 1, rEMS was applied along with

aPRP, and we found the change in mean EZW rate to be 0.7% at the end of 1 year versus baseline. This result suggests that rEMS increases the effects of aPRP. The combined use of rEMS and aPRP has synergistic effects to prevent photoreceptor loss and reactivate the photoreceptor cells in sleep (dormant) mode. The electromagnetic field used here is far below the safety limits set by the World Health Organization [39].

In our study, ellipsoid zone widths and FPD ratios in visual field showed similar changes. This proves that the visual field is related to the

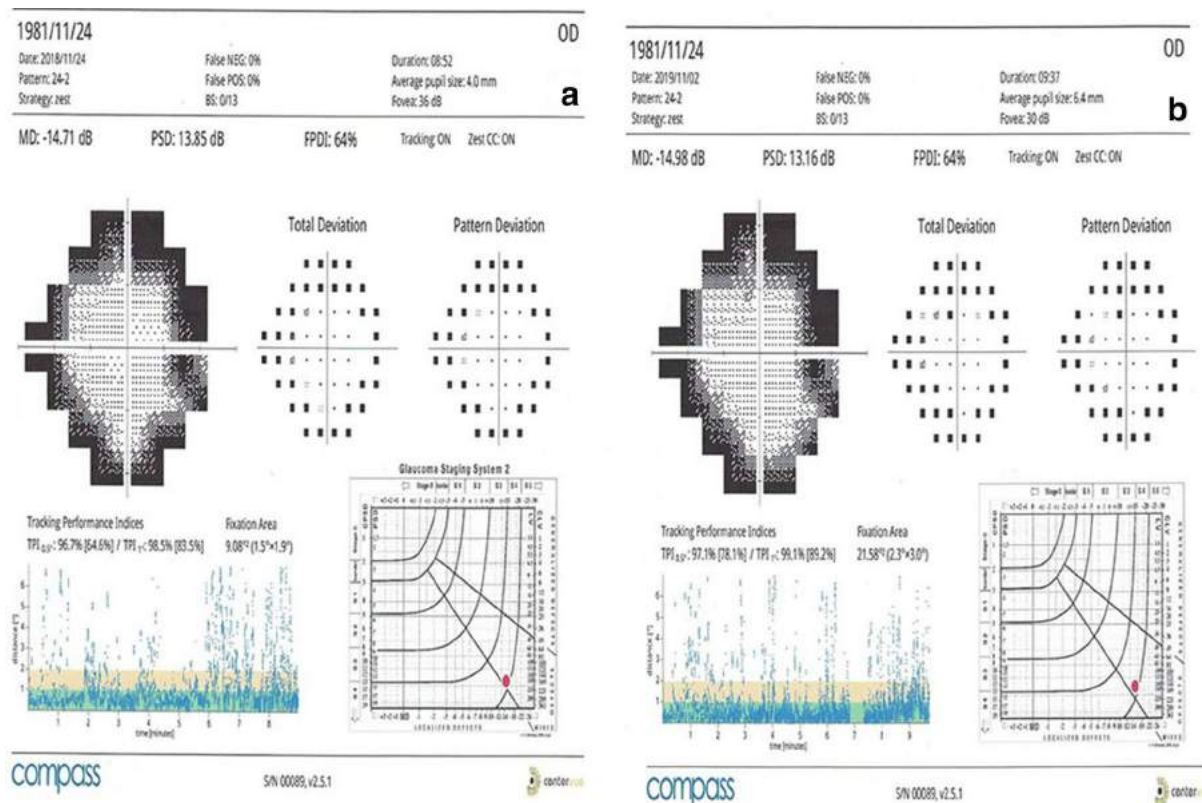


**Fig. 8** Visual field FPDIs changes of a patient with retinitis pigmentosa receiving only aPRP (Table 2, patient no. 1). **a** Before treatment, 24%. **b** The 13th month of follow-up post-treatment, 28%

number of photoreceptors. The visual field is a subjective test and can be influenced by many parameters such as refractive error, media opacity, illumination intensity, the patient's current attention, learning curve, etc. [40]. The visual field test gives indirect data about the number and functions of photoreceptors. EZW is an objective parameter in tracking the number of photoreceptors, it is not affected by subjective situations. We believe that EZW can be used for diagnosis and follow-up as a substitute for visual field and electroretinography in most cases. In our opinion, EZW should be the gold standard diagnostic follow-up criterion for RP.

In contrast to the visual field, the central visual acuity is affected too late in RP. Apoptosis occurring in photoreceptors in the periphery leads to Müller cell hypertrophy and ectopic synaptogenesis in the central 19-degree area. As a result of the paracrine effects of Müller cells, the cone cells are not affected by apoptosis for a long time. Consequently, BCVA can remain stable for a long time [41]. In our study, BCVA in all three groups did not change during an average of 13 months follow-up.

Local and systemic adverse events related to rEMS and/or aPRP were not detected during the 1-year follow-up. Patients did not describe any

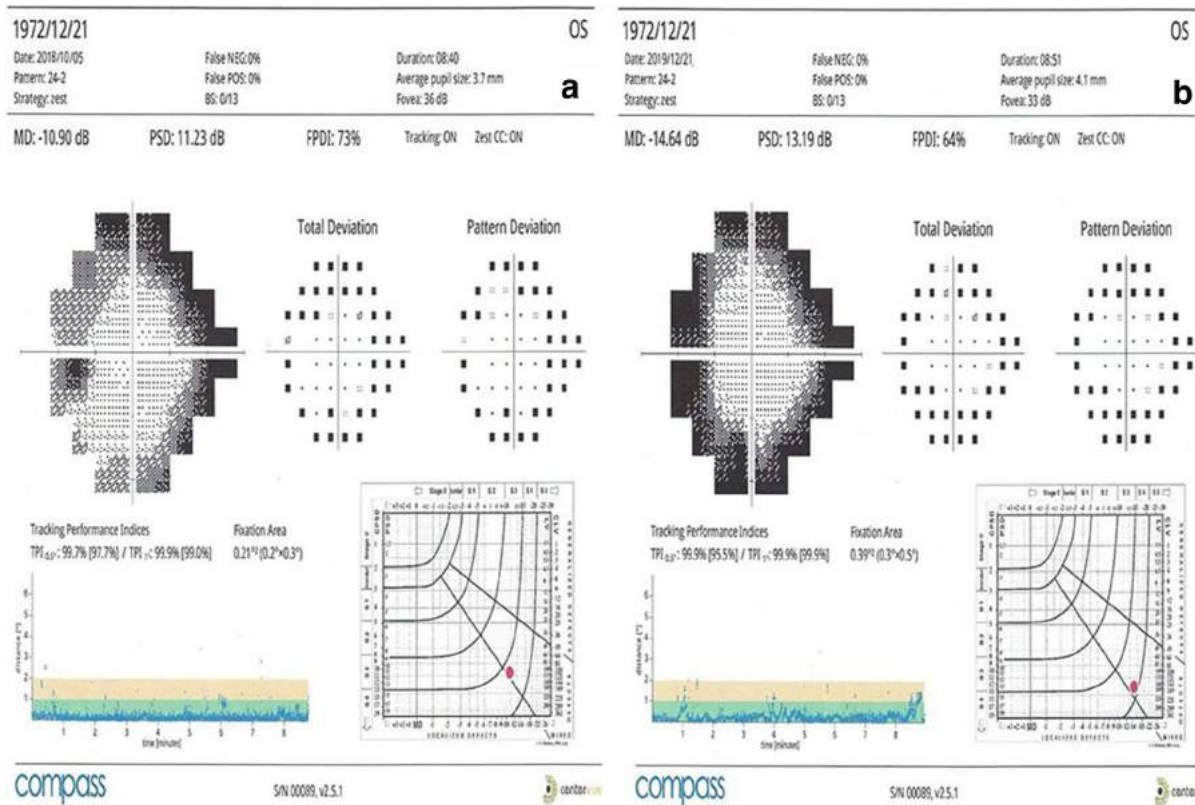


**Fig. 9** Visual field FPDIs changes of a patient with retinitis pigmentosa patient receiving only aPRP (Table 2, patient no. 2). **a** Before treatment, 64%. **b** The 13th month of follow-up post-treatment, 64%

uncomfortable condition except for temporary light sensitivity (which may last several days as a result of aPRP injection) and headache (which may last several hours as a result of rEMS application).

This retrospective clinical study has some limitations. The annual progression rate of retinitis pigmentosa varies depending on the type of genetic mutation. However, this issue was not analyzed here because the genetic mutation analysis of each patient could not be

performed. Inflammatory findings were observed in some genetic mutation types of RP or in some stages of the disease. There were no measurements such as a laser flare meter regarding how aPRP or combined procedures affect the inflammatory response. The progression rate of each genetic type and the effects of interventional procedures on inflammation are additional research topics.



**Fig. 10** Visual field FPDIs changes of a patient with retinitis pigmentosa, natural course (Table 3, patient no. 1). **a** Before treatment, 73%. **b** The 13th month of follow-up post-treatment, 64%

## CONCLUSION

Retinitis pigmentosa is a neurodegenerative genetic disorder with progressive photoreceptor loss. In recent years, growth factor injections, stem cell applications, or gene therapy options have come into clinical use to slow or stop disease progression. Platelet-rich plasma is a good source of growth factors, but its half-life is 4–6 months. aPRP might more effectively slow down photoreceptor loss when repeated as booster injections and combined with retinal electromagnetic stimulation.

## ACKNOWLEDGEMENTS

We thank the participants of the study. We thank Prof. Dr Figen ŞERMET and the staff members of Ankara University Faculty of Medicine, Department of Ophthalmology.

**Funding.** No funding or sponsorship was received for this study or publication of this article. The rapid service fee was funded by the Ankara University Tecnopolis Institute.

**Medical Writing Assistance.** Medical writing and editorial assistance were provided by American Manuscript Editors Company, funded by the authors.

**Authorship.** All named authors meet the International Committee of Medical Journal Editors (ICMJE) criteria for authorship for this article, take responsibility for the integrity of the work as a whole, and have given their approval for this version to be published.

**Disclosures.** All authors had full access to all of the data in this study and take complete responsibility for the integrity of the data and accuracy of the data analysis. Umut Arslan and Emin Özmert have nothing to disclose. Umut

Arslan and Emin Özmert have no conflicts of interest to disclose.

**Compliance with Ethics Guidelines.** Ethics committee approval for the transcranial electromagnetic stimulation study was obtained from the Ankara University Faculty of Medicine Clinical Research Ethics Committee (17-1177-18). This committee had already approved the GFs work (19-1293-18). The study was performed in accordance with the tenets of the 2013 Declaration of Helsinki. Written informed consent was obtained from the patients prior to enrollment.

**Data Availability.** The datasets generated during and/or analyzed during the study are available from the corresponding author on reasonable request.

## REFERENCES

1. Ali MU, Rahman MSU, Cao J, Yuan PX. Genetic characterization and disease mechanism of retinitis pigmentosa; current scenario. *3 Biotech*. 2017;7(4):251–2.
2. Wang AL, Knight DK, Vu TT, Mehta MC. Retinitis pigmentosa: review of current treatment. *Int Ophthalmol Clin*. 2019;59:263–80. <https://doi.org/10.1097/HIO.000000000000256>.
3. Zhang Q. Retinitis pigmentosa. *Asia-Pac J Ophthalmol*. 2016;5:265–71. <https://doi.org/10.1097/apo.0000000000000227>.
4. Hartong DT, Berson EL, Dryja TP. Retinitis pigmentosa. *Lancet*. 2006;368:1795–809. [https://doi.org/10.1016/s0140-6736\(06\)69740-7](https://doi.org/10.1016/s0140-6736(06)69740-7).
5. Yoshida N, Ikeda Y, Notomi S, et al. Clinical evidence of sustained chronic inflammatory reaction in retinitis pigmentosa. *Ophthalmology*. 2013;120:100–5. <https://doi.org/10.1016/j.ophtha.2012.07.006>.
6. Poornachandra B, Khurana AK, Sridharan P, et al. Quantifying microstructural changes in retinitis pigmentosa using spectral domain—optical coherence tomography. *Eye Vis (Lond)*. 2019;15(6):13. <https://doi.org/10.1186/s40662-019-0139-0>.
7. Lima LH, Sallum JM, Spaide RF. Outer retina analysis by optical coherence tomography in cone-rod dystrophy patients. *Retina*. 2013;33:1877–80. <https://doi.org/10.1097/IAE.0b013e31829234e6>.
8. Anitua E, Muruzabal F, Tayebba A, et al. Autologous serum and plasma rich in growth factors in ophthalmology: preclinical and clinical studies. *Acta Ophthalmol*. 2015;93(8):e605–e614614.
9. Amable PR, Carias RB, Teixeira MV, et al. Platelet-rich plasma preparation for regenerative medicine: optimization and quantification of cytokines and growth factors. *Stem Cell Res Ther*. 2013;4(3):67.
10. Arslan U, Özmert E, Demirel S, Örnek F, Şermet F. Effects of subtenon-injected autologous platelet-rich plasma on visual functions in eyes with retinitis pigmentosa: preliminary clinical results. *Graefes Arch Clin Exp Ophthalmol*. 2018;256(5):893–908. <https://doi.org/10.1007/s00417-018-3953-5>.
11. Özmert E, Arslan U. Management of deep retinal capillary ischemia by electromagnetic stimulation and platelet-rich plasma: preliminary clinical results. *Adv Ther*. 2019. <https://doi.org/10.1007/s12325-019-01040-2>.
12. Maziarz A, Kocan B, Bester M, et al. How electromagnetic fields can influence adult stem cells: positive and negative impacts. *Stem Cell Res Ther*. 2016;7:54. <https://doi.org/10.1186/s13287-016-0312-5>.
13. Parate D, Kadir ND, Celik C, et al. Pulsed electromagnetic fields potentiate the paracrine function of mesenchymal stem cells. *Stem Cell Res Ther*. 2020;11:46. <https://doi.org/10.1186/s13287-020-1566-5>.
14. Patruno A, Ferrone A, Costantini E, et al. Extremely low-frequency electromagnetic fields accelerates wound healing modulating MMP-9 and inflammatory cytokines. *Cell Prolif*. 2018;51(2):e12432. <https://doi.org/10.1111/cpr.12432>.
15. Demetriades AM, Deering T, Liu H, et al. Transscleral delivery of antiangiogenic proteins. *J Ocul Pharmacol Ther*. 2008;24(1):70–9. <https://doi.org/10.1089/jop.2007.0061>.
16. Meng T, Kulkarni V, Simmers R, Brar V, Xu Q. Therapeutic implications of nanomedicine for ocular drug delivery. *Drug Discov Today*. 2019. <https://doi.org/10.1016/j.drudis.2019.05.00>.
17. Li SK, Hao J. Transscleral passive and iontophoretic transport: theory and analysis. *Expert Opin Drug Deliv*. 2017;15(3):283–99. <https://doi.org/10.1080/17425247.2018.1406918>.
18. Luo J, Zheng H, Zhang L, et al. High-frequency repetitive transcranial magnetic stimulation (rTMS)

- improves functional recovery by enhancing neurogenesis and activating BDNF/TrkB signaling in ischemic rats. *Int J Mol Sci.* 2017;18(2):455. <https://doi.org/10.3390/ijms18020455>.
19. Mysona BA, Zhao J, Bollinger KE. Role of BDNF/TrkB pathway in the visual system: therapeutic implications for glaucoma. *Expert Rev Ophthalmol.* 2017;12(1):69–81.
  20. Takahashi VKL, Takiuti JT, Carvalho-Jr JRL, et al. Fundus autofluorescence and ellipsoid zone (EZ) line width can be an outcome measurement in RHO-associated autosomal dominant retinitis pigmentosa. *Graefes Arch Clin Exp Ophthalmol.* 2019;257:725–31. <https://doi.org/10.1007/s00417-018-04234-6>.
  21. Cai CX, Locke KG, Ramachandran R, Birch DG, Hood DC. A comparison of progressive loss of the ellipsoid zone (EZ) band in autosomal dominant and x-linked retinitis pigmentosa. *Invest Ophthalmol Vis Sci.* 2014;23(55):7417–22. <https://doi.org/10.1167/iovs.14-15013>.
  22. Sandberg MA, Rosner B, Weigel-DiFranco C, Dryja TP, Berson EL. Disease course of patients with X-linked retinitis pigmentosa due to RPGR gene mutations. *Invest Ophthalmol Vis Sci.* 2007;48:1298–304.
  23. Takahashi VKL, Xu CL, Takiuti JT, et al. Comparison of structural progression between ciliopathy and non-ciliopathy associated with autosomal recessive retinitis pigmentosa. *Orphanet J Rare Dis.* 2019;14:187. <https://doi.org/10.1186/s13023-019-1163-9>.
  24. Friberg TR. Natural course of retinitis pigmentosa over a three-year interval. *Am J Ophthalmol.* 1985;100(4):621–2.
  25. Birch DG, Anderson JL, Fish GE. Yearly rates of rod and cone functional loss in retinitis pigmentosa and cone-rod dystrophy. *Ophthalmology.* 1999;106:258–68.
  26. Fuhrmann S, Zou CJ, Levine EM. Retinal pigment epithelium development, plasticity, and tissue homeostasis (Invited review for *Experimental Eye Research*). *Exp Eye Res.* 2014;123:141–50. <https://doi.org/10.1016/j.exer.2013.09.003>.
  27. Strauss O. The retinal pigment epithelium in visual function. *Physiol Rev.* 2005;85:845–81. <https://doi.org/10.1152/physrev.00021.2004>.
  28. Cacaes PS, Boulan ER. Retinal pigment epithelium polarity in health and blinding diseases. *Curr Opin Cell Biol.* 2020;62:37–45.
  29. Dalvi S, Galloway CA, Singh R. Pluripotent stem cells to model degenerative retinal diseases: the RPE perspective. In: Bharti K, editor. *Pluripotent stem cells in eye disease therapy, advances in experimental medicine and biology.* Cham: Springer Nature Switzerland; 2019. p. 1186. <https://doi.org/10.1007/978-3-030-28471-8>.
  30. Collins MK, Perkins GR, Rodriguez-Tarduchy G, Nieto MA, López-Rivas A. Growth factors as survival factors: regulation of apoptosis. *Bioessays.* 1994;16(2):133–8.
  31. Julian JL, Bauer DE, Kong M, et al. Growth factor regulation of autophagy and cell survival in the absence of apoptosis. *Cell.* 2005;120(2):237–48.
  32. Munder MC, Midtvedt D, Franzmann T, et al. A pH-driven transition of the cytoplasm from a fluid- to a solid-like state promotes entry into dormancy. *eLife.* 2016;5:e09347.
  33. Koenekoop RK. Why some photoreceptors die, while others remain dormant: lessons from RPE65 and LRAT associated retinal dystrophies. *Ophthalmic Genet.* 2011;32:126–8.
  34. Wang W, Lee SJ, Scott PA, et al. Two-step reactivation of dormant cones in retinitis pigmentosa. *Cell Rep.* 2016;15:372–85.
  35. Papait A, Cancedda R, Mastrogiacomo M, Poggi A. Allogeneic platelet-rich plasma affects monocyte differentiation to dendritic cells causing an anti-inflammatory microenvironment, putatively fostering wound healing. *Tissue Eng Regen Med.* 2018;12(1):30–433. <https://doi.org/10.1002/term.2361>.
  36. Reed GL, Fitzgerald ML, Polgár J. Molecular mechanisms of platelet exocytosis: insights into the B secrete life of thrombocytes. *Blood.* 2000;96(10):3334–42.
  37. Anitua E, Muruzabal F, Alcaide M-L, Orive G. Plasma rich in growth factors (PRGFs-Endoret) stimulates corneal wound healing and reduces haze formation after PRK surgery. *Exp Eye Res.* 2013;115:153–61.
  38. Limoli PG, Limoli C, Vingolo EM, Scalinci SZ, Nebbioso M. Cell surgery and growth factors in dry age-related macular degeneration: visual prognosis and morphological study. *Oncotarget.* 2016;7(30):46913–23.
  39. Chandra T, Chavhan GB, Sze RW, et al. Practical considerations for establishing and maintaining a magnetic resonance imaging safety program in a pediatric practice. *Pediatr Radiol.* 2019;49(4):458–68. <https://doi.org/10.1007/s00247-019-04359-8>.

40. Wu Z, Medeiros FA. Recent developments in visual field testing for glaucoma. *Curr Opin Ophthalmol*. 2018;29(2):141–6. <https://doi.org/10.1097/ICU.0000000000000461>.
41. Michalakis S, Schäferhoff K, Spiwoks-Becker I, et al. Characterization of neurite outgrowth and ectopic synaptogenesis in response to photoreceptor dysfunction. *Cell Mol Life Sci*. 2013;70(10):1831–47.