



# Management of Deep Retinal Capillary Ischemia by Electromagnetic Stimulation and Platelet-Rich Plasma: Preliminary Clinical Results

Emin Özmert · Umut Arslan

Received: June 16, 2019  
© Springer Healthcare Ltd., part of Springer Nature 2019

## ABSTRACT

**Introduction:** To investigate the efficacy of retinal electromagnetic stimulation and sub-tenon autologous platelet-rich plasma in the treatment of deep retinal capillary ischemia.

**Methods:** The study included 28 eyes of 17 patients aged 15–76 years (mean 37.9 years) who had deep retinal capillary ischemia. Patients who had acute-onset paracentral scotoma in the last 1 month were included in the study between January 2018 and January 2019. The diagnosis of deep retinal capillary ischemia was based on clinical history and typical findings of optical coherence tomography angiography. The eyes were divided into three groups: group 1 ( $n = 7$  eyes) received electromagnetic stimulation alone; group 2 ( $n = 7$  eyes) received electromagnetic stimulation and sub-tenon autologous platelet-rich plasma injection; group 3 had no intervention and served as a control group ( $n = 14$  eyes). The patients underwent ten

sessions of electromagnetic stimulation in groups 1 and 2. Sub-tenon autologous platelet-rich plasma injection was performed immediately after the first, fifth, and tenth sessions of electromagnetic stimulation in group 2. The deep retinal capillary density and best corrected visual acuity changes were investigated before and after treatment at the first month.

**Results:** The mean deep retinal capillary density was 52.0% before electromagnetic stimulation and 56.1% after ten sessions of application in group 1; this improvement was statistically significant ( $p = 0.01$ ). In the combined treatment group (group 2), the mean deep retinal capillary density was 46.9% before the treatment and 56.5% after the treatment; this increase was also statistically significant ( $p = 0.01$ ). Statistically significant best corrected visual acuity improvement ( $p = 0.01$ ) could be achieved only in group 2. The combined treatment was significantly superior ( $p < 0.01$ ) to treatment with only electromagnetic stimulation regarding best corrected visual acuity and deep retinal capillary density. In the control group (group 3), there was no statistically significant change ( $p = 0.09$ ) in the mean deep retinal capillary density and best corrected visual acuity.

**Conclusion:** Treatment of the underlying cause is a priority in the treatment of deep retinal capillary ischemia. However, in the acute period, local ischemia treatment is necessary to prevent permanent retinal damage and

**Enhanced digital features** To view enhanced digital features for this article go to <https://doi.org/10.6084/m9.figshare.8964386>.

E. Özmert  
Department of Ophthalmology, Faculty of  
Medicine, Ankara University, Ankara, Turkey

U. Arslan (✉)  
Ankara University Technopolis, Ankara, Turkey  
e-mail: drumutarслан@hotmail.com;  
bioretina.net@gmail.com

scotomas. In mild cases, only electromagnetic stimulation, which is non-invasive and easy to use, might have a beneficial effect on deep retinal capillary density. In more severe cases, sub-tenon fresh autologous platelet-rich plasma injection together with electromagnetic stimulation may be more effective in the treatment of local ischemia of the retina in order to augment the response.

**Funding:** The Rapid Service Fees were funded by the Ankara University Tecnopolis Institute.

**Clinical Trial Registration:** [titck.gov.tr](http://titck.gov.tr) identifier, 2018-136.

**Keywords:** Acute macular neuroretinopathy; Deep retinal capillary ischemia; Electromagnetic stimulation; Magnovision; Ophthalmology; Paracentral acute middle maculopathy; Platelet-rich plasma

## INTRODUCTION

Deep retinal capillary ischemia (DRCI) is a recently described entity in patients presenting with an acute-onset paracentral scotoma. Sub-clinical macular lesions of DRCI were formerly best visualized on near-infrared reflectance imaging. The development of optical coherence tomography angiography (OCTA) has facilitated studies of the retinal capillary structures [1]. The multiplanar superficial capillary plexus is located in the inner plexiform layer (IPL) and contains synapses between bipolar and ganglion cells as well as amacrine cells [2, 3]. The deep capillary plexus (DCP) is located in the outer plexiform layer (OPL), which is thinner than the IPL. The DCP is composed of synapses of photoreceptors, bipolar cells, and horizontal cells [2]. This area is also at the border of the oxygen diffusion from the choroid [4]. It is likely that the oxygen coming from the choroid has been completely consumed by the photoreceptors because of the low partial pressure of oxygen level in the outer nuclear layer (ONL). The DCP supplies both the bipolar cells and the synaptic structure of the OPL and Henle fibers [4].

Deep retinal capillary ischemia is an ischemic event in the middle and deep layers of

the retina due to various systemic or local vascular pathologies. It is obvious in the intraretinal hyper-reflective bandlike zone located superior or inferior to the OPL conjointly on a structural cross-sectional B-scan of the spectral domain optical coherence tomography (SD-OCT) examination along with an acute-onset paracentral scotoma and subjective complaints of the patient [5]. Ophthalmologists often face a significant diagnostic challenge because of a lack of noticeable changes in the appearance of the retina.

Deep retinal capillary ischemia has two different appearances on B-scan SD-OCT exams according to the level of the involved DCP. If the hyper-reflective bandlike zone is located on the outer plexiform layer–inner nuclear layer (OPL–INL) junction, then it is termed paracentral acute middle maculopathy (PAMM) or type 1 deep retinal capillary ischemia. If the hyper-reflective band is seen on the OPL–ONL junction, then it is termed type 2 deep retinal capillary ischemia. This might be a new variant of acute macular neuroretinopathy (AMN). These intraretinal hyper-reflective zones are seen as patchy areas of various patterns on en face OCT image, and atrophic areas in the inner and the outer nuclear layer, respectively, are developed in the late stage of the diseases [6–9]. The pathophysiologic features of DCP ischemia are considered to be ischemic hypoxia leading to cell death with swelling of the middle retinal tissues. This may lead to severe vision loss and permanent paracentral scotoma depending on the underlying cause and depth of ischemia [10–17]. It can also be observed by slowing metabolic activity in photoreceptors and neural retina. The metabolic slowdown is defined as a dormant phase in photoreceptors and OFF mode in the neural retina [18–20].

The retinal deep capillary plexus is a single monoplanar capillary plexus located in the OPL. It has the lowest vessel density—this is a significant finding that might be used to evaluate retinal vascular diseases accurately [21]. For this reason, the changes in the percentage of the vessel density in DCP during the follow-up were preferred as an assessment parameter of the treatment modalities used in this prospective clinical study.

Platelets are anucleated cells that contain many types of growth factors including platelet-derived growth factor (PDGF), transforming growth factor beta (TGF- $\beta$ ), vascular endothelial growth factor (VEGF), and epidermal growth factor (EGF) in alpha granules [22–25]. Thus, the supplementation of growth medium with autologous platelet-rich plasma (aPRP) could be desirable for clinical applications and could lead to some functional improvement [26].

High-frequency repetitive electromagnetic stimulation (rEMS) has promising therapeutic potential in ischemic neurological patients. The rationale of rEMS is that it modulates neural excitability and increases neural plasticity; thus, it improves the functional outcome [27–29]. These neuroprotective effects of rEMS are dependent on the increase in the level of brain-derived neurotrophic factor (BDNF), VEGF, and increased tyrosine kinase A, B, and C (TrkA, TrkB, and TrkC) receptor activation [29, 30]. Therefore, high-frequency rEMS might be a promising therapeutic strategy for ischemic retinal disorders such as DRCI [31, 32].

There is no known and proven specific treatment for DRCI to date except for systemic checkups and treatment of the underlying diseases or predisposing factors. The aim of this preliminary clinical study is to investigate the efficacy of high-frequency rEMS alone or in combination with sub-tenon fresh aPRP as a treatment modality in the treatment of DRCI. To the best of our knowledge, this is the first prospective clinical trial on this subject in the ophthalmic literature.

## METHODS

Ethics committee approval for the transcranial electromagnetic stimulation study was obtained from the Ankara University Faculty of Medicine Clinical Research Ethics Committee (17-1177-18) as well as and Review Board of the Drug and Medical Device Department within the Turkish Ministry of Health (2018-136). These committees had already approved the aPRP work (12-595-16 and 16-AKD-30). The study was performed in accordance with the tenets of the 1964 Declaration of Helsinki. Written informed

consent was obtained from the patients prior to enrollment.

This prospective, open-label preliminary clinical trial was conducted between January 2018 and January 2019 at Ankara University Faculty of Medicine, Department of Ophthalmology. The study included 28 eyes of 17 patients who had either type 1 or type 2 DRCI with some coexisting relevant ocular symptoms. The preliminary diagnosis was based on the clinical history, patients' complaints, and typical appearance of hyper-reflective band on the structural cross-sectional B-scan SD-OCT. All patients enrolled in this study underwent a complete routine ophthalmic examination including best-corrected visual acuity (BCVA) measurement with the ETDRS chart (Topcon CC 100 XP, Japan). The patients were further evaluated with OCTA to confirm the diagnosis of DRCI (RTVue XR "Avanti", Optovue, Fremont, CA, USA), which provides a typical multimodal imaging platform. The vessel densities (in percent) of deep capillary plexus before and after the treatments or in the control group at baseline and last examination were measured with the "AngioAnalytic" feature of the OCTA device. To compare the percentage of the vessel densities precisely during follow-up, the "Link-B Scans" button on the screen was activated so that the exact same segmentation planes of the DCP could be compared. The OCTA device automatically calculated and displayed the vessel density maps as follow-up sequences (Angio Retina multiscan view) and trend analysis.

## Subjects

We enrolled patients complaining of blurred vision and/or acute-onset paracentral scotoma during the last month without any visible fundus change along with typical SD-OCT and OCTA findings.

Patients were excluded from the study if one of the following was found:

- The presence of noticeable changes in the fundus examination
- Any optic media opacity that may cause artifacts on OCTA images and interfere with

quantitative measurements of the DCP vessel density

- Complaining of paracentral scotoma lasting more than 1 month (in order to exclude chronic changes in the retinal tissue)
- Presence of atrophic changes in INL or ONL on cross-sectional B-scan SD-OCT

The total number of 28 eyes (17 patients) with DRCI were enrolled into three groups according to the BCVA and treatment approach(s):

- Group 1: Comprised patients having fairly good BCVA (92 or better letters, ETDRS) and acute-onset paracentral scotoma(s). Because of non-invasive and easy-to-use features, only rEMS was preferred as the initial step. It was applied to 7 eyes on 10 consecutive days with a specifically designed helmet producing and applying electromagnetic stimulation to the retina without touching the scalp or the eyelids.
- Group 2: Comprised patients having decreased BCVA (89 or worse letters, ETDRS) and acute-onset paracentral scotoma(s). In those seriously affected patients, in order to augment the effect of the rEMS, sub-tenon aPRP injection was added. rEMS was applied to 7 eyes on 10 consecutive days. In addition, the eyes were injected with sub-tenon fresh aPRP on days 1, 5, and 10.
- Group 3: Comprised patients who refused to receive either rEMS or aPRP therapies with various BCVA and acute-onset paracentral scotoma(s). These eight patients' 14 eyes served as control group, and existing systemic disorder(s) were consulted and treated accordingly.

In all of the three groups, BCVA and vessel density measurements were done at baseline and on the first month. In the treatment groups, at baseline, therapies were given just after the measurements. There was an

observation period without any intervention between day 10 and the first month.

### Preparation and Injection of Autologous Platelet-Rich Plasma

We used the single-spin protocol for preparing aPRP. About 20 ml of blood was drawn from the patient's antecubital vein and inserted into two 10-ml Vacutainer tubes that contain trisodium citrate (T-LAB PRP Kit, T-Biyoteknoloji, Bursa, Turkey). These tubes were placed in a refrigerated (+ 4 °C) centrifuge (Nüve NF 1200R, Nüve Laboratuar Teknolojileri, Ankara, Turkey) and spun at 2500 rpm (580 × g) for 8 min within 30 min of collection. Three different layers formed in the tubes: red blood cells at the bottom, platelet-rich plasma in the middle, and platelet-poor plasma in the top layer. A total of 1.5 ml of the middle layer (which mainly contained platelets) was withdrawn by syringe and immediately injected into the sub-tenon space of each eye after topical anesthesia with proparacaine hydrochloride (Alcaine, Alcon, USA) drops.

The preparation and injection of the PRP were performed by the same ophthalmologist (UA) under topical anesthesia and sterile conditions. The subjects were asked to look in an inferonasal direction, and the 1.5-ml injection of aPRP was performed under the tenon space in the superotemporal quadrant using a 25-gauge needle. This site was preferred for injection because of its easy access and relatively wide absorption area [26].

### Retinal Electromagnetic Stimulation

A high-frequency rEMS protocol has been defined in the literature [31, 32] and was applied in groups 1 and 2 via a novel device developed specifically for ophthalmic usage (Magnovision™, Bioretina Biyoteknoloji AŞ, Ankara, Turkey). The patients underwent ten consecutive sessions of rEMS application. Parameters for the treatment were 42 Hz frequency, 30 min of duration, and mild operating cycle. The power of the electromagnetic field was 2000 mG, which is a very low dose and

**Table 1** General characteristics of the groups according to the interventions ( $n = 28$  eyes of 17 patients)

	Intervention	Gender (female/male)	Mean age (years) (range)	Follow-up (months)
Group 1 ( $n = 7$ )	rEMS	4/3	34.1 (15–74)	1
Group 2 ( $n = 7$ )	rEMS + aPRP	4/3	40.8 (15–76)	1
Group 3 ( $n = 14$ )	No ocular treatment <sup>a</sup>	4/4	38.8 (17–75)	1

rEMS repetitive electromagnetic stimulation of the retina, aPRP autologous platelet-rich plasma injection into sub-tenon space immediately after first, fifth, and tenth sessions of rEMS application in group 2

<sup>a</sup> There is no local or regional treatment. If any underlying systemic disease was detected, then it was treated accordingly

within the safety limits of World Health Organization [33, 34]. In group 2, sub-tenon aPRP injections were also performed immediately after the first, fifth, and tenth sessions of rEMS application.

### Statistical Analysis

The changes in deep retinal capillary density (DRCD) and BCVA before and after the interventions were compared. Statistical analysis was performed using SPSS for Windows (v.22, IBM Corp., Armonk, NY, USA). The results were presented as the mean  $\pm$  standard deviation. The differences in the vessel density and BCVA in each group were analyzed using the Wilcoxon signed rank test. A Mann–Whitney  $U$  test analysis was also performed to determine the vessel density and BCVA changes between the groups. In this study,  $p$  values smaller than 0.05 were considered to be statistically significant.

The primary outcome measure of the study is to assess the therapeutic effect of the electromagnetic stimulation alone or combined with sub-tenon aPRP in cases with DRCI via a comparison of the BCVAs and vessel densities of DCPs. The secondary outcome measure is to assess whether a combined application of rEMS and aPRP has a better outcome versus the application of rEMS alone.

## RESULTS

Of the 17 patients, 9 were male and 8 were female: their mean age was 37.9 years (range 15–76 years). The mean age was 34.1 (15–74) in group 1, 40.8 (15–76) in group 2, and 38.8

(17–75) in group 3 (Table 1). Gender ratios and age ranges were comparable in the three groups.

DRCs (%) and BCVAs before and after the treatment modalities were displayed in Table 2 according to demographic characteristics and medical status in group 1 and group 2 (total 14 eyes of 9 patients). The demographic characteristics, medical status, and initial and last values of BCVAs and DRCs (%) without any ocular treatment in group 3 (control group) are listed in Table 3. The distribution of the 17 patients and 28 eyes according to the applied treatments was as follows:

- 5 patients: received rEMS in one eye, rEMS + aPRP in the other eye (total ten eyes)
- 2 patients: received rEMS in one eye (total two eyes)
- 2 patients: received rEMS + aPRP in one eye (total two eyes)
- 8 patients: 14 eyes served as control group without any ocular treatment

The mean DRCD was 52.0% before rEMS and 56.1% after ten sessions of application in group 1; this improvement was statistically significant ( $p = 0.01$ ) (Fig. 1). In the combined treatment group (group 2), the mean DRCD was 46.9% before the treatment and 56.5% after the treatment; this increase was also statistically significant ( $p = 0.01$ ) (Fig. 2). Statistically significant BCVA improvement ( $p = 0.01$ ) could be achieved only in group 2 (Table 4).

In the control group (group 3), the mean DRCD was 52.7% before the treatment and 50.3% after the treatment; this change was statistically not significant ( $p = 0.09$ ) (Fig. 3). BCVA changes ( $p = 0.99$ ) were statistically not significant in group 3 (Table 4).



**Table 2** Demographic characteristics and medical status of the treated patients, treatment modalities, and evaluated parameters

Patient no.	Age/gender	Medical status	Eye ( <i>n</i> = 14)	Treatment	DRCD		BCVA	
					Before	After	Before	After
1	21 F	Pernicious anemia	R	PRP + rEMS	51.0	61.0	65	105
			L	rEMS	48.6	52.3	65	100
2	40 M	Renal hypertension	R	rEMS	55.0	58.4	95	100
3	15 F	Atrial septal defect	R	rEMS	53.3	55.5	65	95
			L	PRP + rEMS	45.0	55.6	50	95
4	33 M	Thoracic trauma	R	rEMS	53.8	58.2	105	105
			L	PRP + rEMS	51.1	59.6	100	105
5	20 F	Oral contraceptive	R	PRP + rEMS	52.1	61.6	100	105
			L	rEMS	53.9	61.1	105	105
6	74 F	Cardiac arrhythmia	R	rEMS	42.2	44.8	95	95
			L	PRP + rEMS	42.8	49.2	89	95
7	36 M	Head trauma	R	rEMS	57.2	62.3	105	105
8	47 M	Retinal detachment surgery	L	PRP + rEMS	39.7	52.3	50	70
9	76 M	Retinal detachment surgery	R	PRP + rEMS	46.9	55.9	50	65

Follow-up 1 month. Treatment group composed of groups 1 and 2, 14 eyes of 9 patients  
*DRCD* deep retinal capillary density (%), *BCVA* best corrected visual acuity (ETDRS letters)

The combined treatment with rEMS and aPRP was significantly superior ( $p < 0.01$ ) to treatment with only rEMS regarding BCVAs and DRCDs improvements.

There were no adverse events or complaints related to application of either electromagnetic stimulation or aPRP.

## DISCUSSION

Deep retinal capillary ischemia can occur concomitantly with vascular occlusive events including cardiac arrhythmia, embolus, thrombus, inflammatory or traumatic vessel wall damage, and vasospasm [8–13]. Additional possible associations have been described such as dengue fever, anemia, ulcerative colitis, thrombocytopenia, lupus, and leukemia [14–17]. Deep retinal capillary ischemia may be acute or acute exacerbations of a chronic

process such as severe anemia, chronic hypertension, arteriovenous malformations, vitamin B<sub>12</sub>, or vitamin D deficiency [9]. In both acute and acute exacerbations of chronic conditions, the patient describes a sudden onset of paracentral scotoma and a deterioration in visual quality. This can lead to infarcts in the neural or sensory retina [6]. In some cases, visual acuity measurements may be complete, but the patient can complain of visual disturbances with a normal appearing fundus. Therefore, correct and early diagnosis might be challenging in many cases. In these suspected cases, careful B-scan SD-OCT assessment is necessary to see if there is a hyper-reflective bandlike zone above or below the OPL. We can detect the pathognomonic findings in the deep capillary plexus slab of the OCTA.

In retinal large vessel obstruction, capillary reperfusion may never occur, causing severe acute impairment of flow within the DCP. But

**Table 3** Demographic characteristics and medical status of the control group (group 3) and evaluated parameters (composed of 14 eyes from 8 patients)

Patient no.	Age/gender	Medical status	Eye ( <i>n</i> = 14)	DRCD		BCVA	
				Initial	Last	Initial	Last
1	17 F	Thalassemia minor	R	49.1	47.3	80	80
			L	48.2	47.6	80	80
2	39 M	Cardiac arrhythmia	R	48.6	47.3	105	105
			L	47.8	46.8	105	105
3	21 F	Oral contraceptive	R	56.1	47.9	74	74
			L	55.3	49.8	74	74
4	75 F	Hypertensive attack	R	50.6	43.1	100	100
			L	51.8	49.0	100	100
5	42 M	Uncontrolled hypertension	R	57.9	57.6	105	105
			L	57.9	57.6	105	105
6	37 M	Head trauma	L	59.8	58.7	105	105
7	71 M	Uncontrolled hypertension	R	47.9	47.6	105	105
8	24 F	Oral contraceptive	R	52.8	51.4	105	105
			L	53.7	52.6	105	105

Follow-up 1 month. Control group did not receive any local/regional therapy, only systemic disorder was treated  
*DRCD* deep retinal capillary density (%), *BCVA* best corrected visual acuity (ETDRS letters)

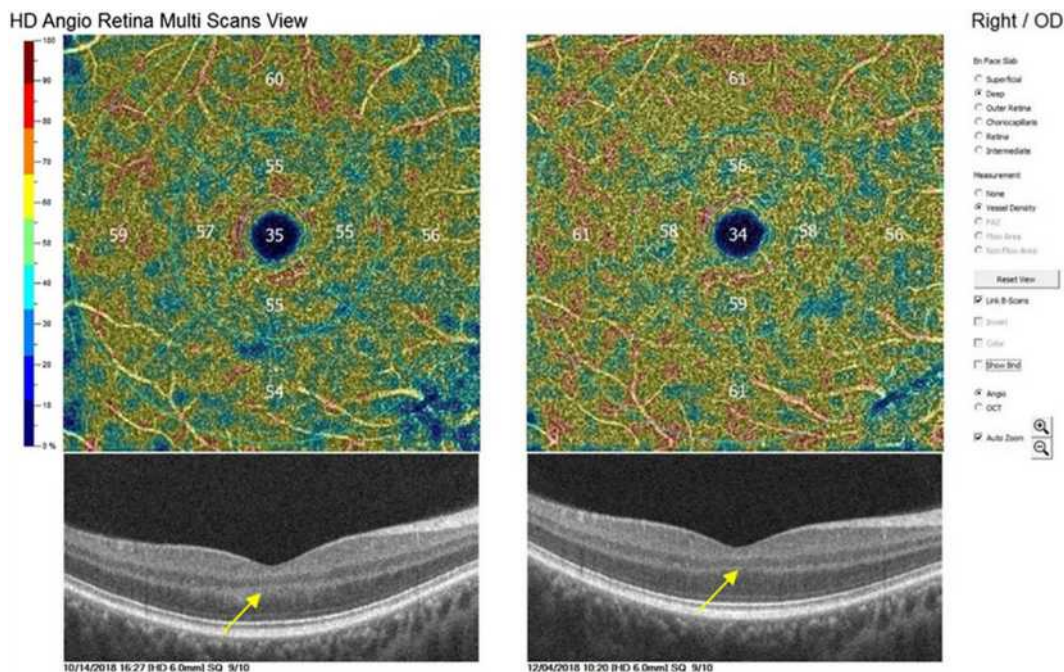
in cases with DRCI, the pathogenesis may be related to ischemia–reperfusion injury. Ischemia disappears with persistent capillary flow in some focal acute lesions, and reperfusion occurs together with low grade inflammation damaging the retina. With time, hyper-reflective bandlike zone disappears, and subsequent atrophy of middle retinal layers associated with permanent loss of the DCP is seen [13, 35].

When nutritional and microenvironmental balance is disrupted, retinal neurons and photoreceptors develop a condition called dormant phase or OFF mode. At this stage, the cells are viable but dysfunctional. If local ischemia and unstable microenvironment persist for a long time, oncosis occurs. Oncosis is the swelling and permanent death of cells by taking up fluid. Regulation of the local ischemia and inflammatory cytokines before the development of oncosis allows the cells in dormant phase (sleep

mode) to switch to the active phase (ON mode) [18–20].

In the case of DRCI, the underlying systemic risk factors should be investigated and treated urgently to prevent the development of permanent scotomas and vital systemic events. There is no proven treatment for DRCI yet except for treating and/or controlling the underlying systemic cause(s). We hypothesized that in mild cases with rEMS, in more severe cases with combined therapy (in order to augment the therapeutic effect of the rEMS, the aPRP therapy was added), it might be possible to increase the capillary flow and suppress and regulate the associated inflammation. Indeed, our favorable findings in terms of DRCD and BCVA supported our hypothesis significantly.

The preclinical and clinical use of aPRP in ophthalmology has encouraged practitioners to use it through sub-tenon injection in the treatment of some retinal diseases [26]. Platelets are



**Fig. 1** DRCD and BCVA changes before and after only Magnovision therapy. Hyper-reflective band in ONL connected with OPL disappeared after the therapy without

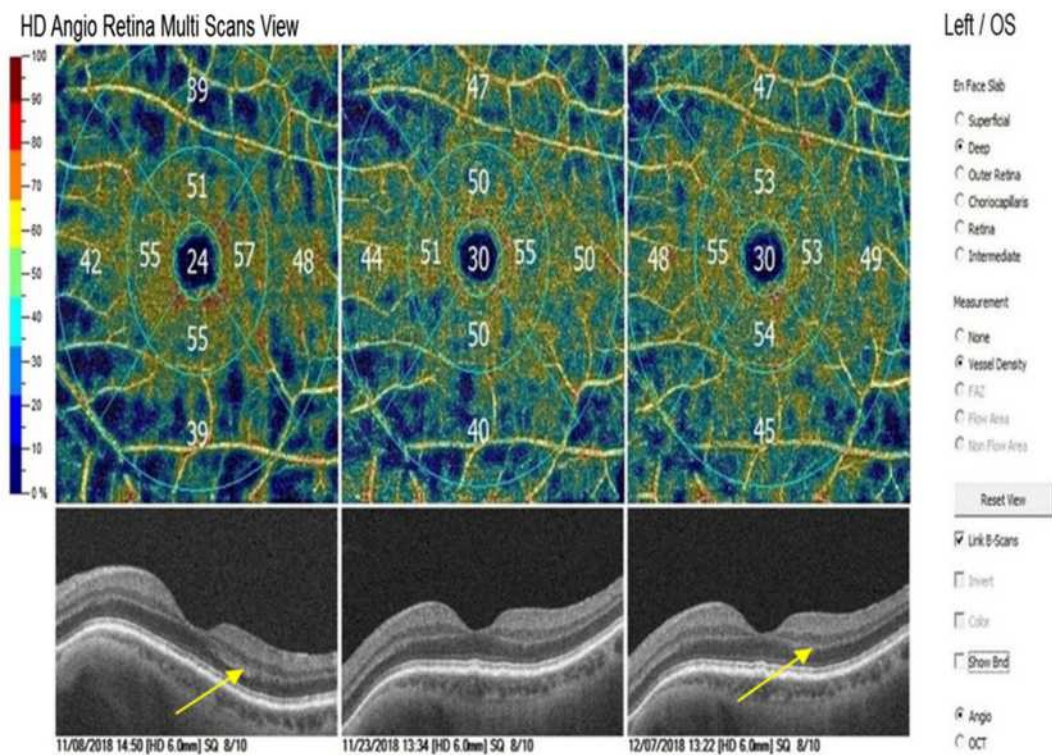
any atrophy (arrows) (Table 2—Patient 2, DRCD 55% to 58.4%/BCVA 95 to 100 ETDRS letters)

part of the blood and contain more than 5000 proteins. About 300 of the contained proteins—especially growth factors and cytokines—are released upon activation [23–25]. Through the sub-tenon injection of aPRP, the release of cytokines, chemokines, and growth factors induces proliferation and activation of reparative cells [23–26]. The level of neurotrophic growth factors may be increased in the microenvironment around the photoreceptors to potentially reactivate photoreceptors that are in sleep mode [26].

It is known that growth factors can pass through the sclera via activation of tyrosine kinase (Trk) receptors, which are commonly found around the limbus, uveoscleral tract, muscle insertions, and optic nerve [36–39]. Molecules smaller than 75 kDa can pass passively through the sclera to the subretinal space. Larger proteins can pass through the sclera by changing the electrical charges by means of the electrical/electromagnetic iontophoresis. These various molecules in the subretinal space activate the cells in the dormant phase [40–44].

The effects of rEMS on local ischemia include increased tissue perfusion, synthesis of growth factors, and enhanced Trk receptor activities [27–32]. The synthesis and affinity of Trk receptors also increase with EMS [29]. Repetitive magnetic stimulation has been used in neurological studies for more than 30 years and magnetotherapy for eye diseases for more than 20 years. The two main effects of this treatment modality make it efficient in the treatment of these disease. The first effect is that it increases the capillary blood flow in the neural tissues. The second effect is that it increases the affinity and activity of growth factor-tyrosine kinase receptors; and it accelerates the effect of growth factors responsible for tissue reparation [31, 32, 45–49]. Electromagnetic stimulation alone or together with aPRP applications might be used in cases with DRCI similar to the treatment of ischemic neurologic conditions [29, 30]. Here, we used the Magnovision™ for electromagnetic stimulation of the retina, optic nerve, and visual pathways similar to the ischemic neurologic diseases. This is a novel device designed specifically for ophthalmic





**Fig. 2** DRCD and BCVA changes before and after combined sub-tenon PRP + Magnovision therapy. Hyperr-reflective band in OPL disappeared after the therapy without any atrophy (arrows) (Table 2—Patient 6, DRCD 42.8% to 49.2%/BCVA 89 to 95 ETDRS letters)

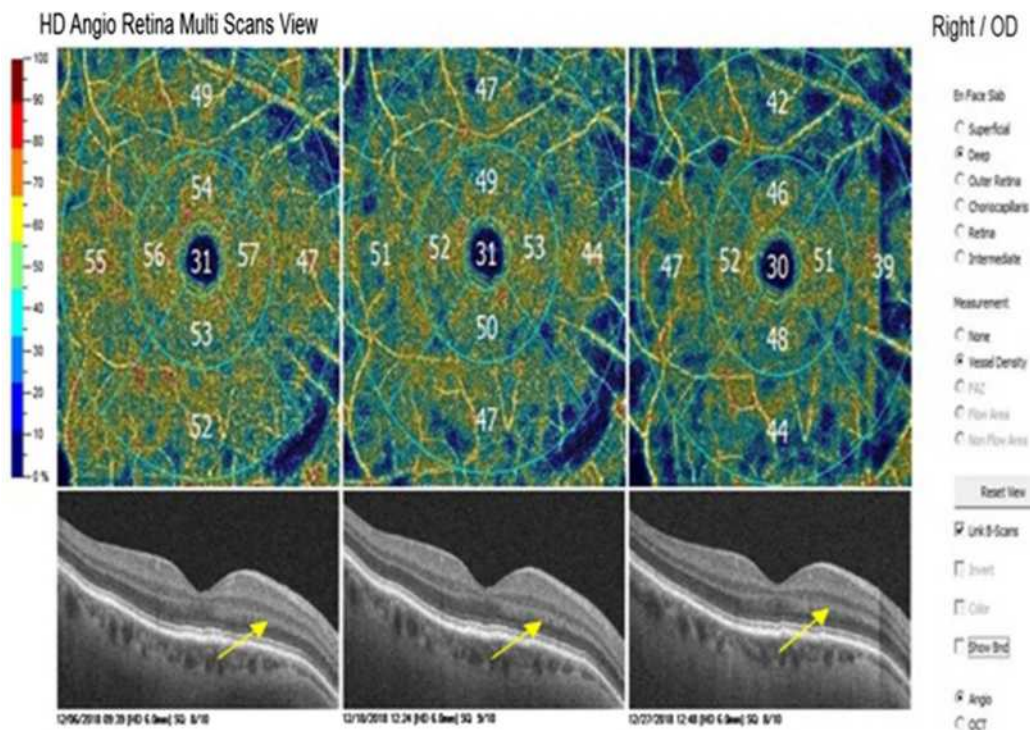
**Table 4** Deep retinal capillary density and best corrected visual acuity changes in three groups ( $n = 28$  eyes of 17 patients)

Group	DRCD		$p$	BCVA		$p$
	Initial	Last		Initial	Last	
1 rEMS alone ( $n = 7$ )	52.0 ± 5.5	<b>56.1 ± 6.0</b>	<b>0.01*</b>	90.7 ± 4.13	100.7 ± 4.5	0.14
2 rEMS + aPRP ( $n = 7$ )	46.9 ± 4.7	<b>56.5 ± 4.6</b>	<b>0.01*</b>	72.0 ± 13.6	<b>93.6 ± 13.4</b>	<b>0.01*</b>
3 Control ( $n = 14$ )	52.7 ± 4.2	50.3 ± 4.7	0.09	96.3 ± 12.9	96.3 ± 12.9	0.99

Follow-up 1 month. Control group did not receive any local/regional therapy; only systemic disorder was treated  
*DRCD* deep retinal capillary density (%), *BCVA* best corrected visual acuity (ETDRS letters), *rEMS* repetitive electro-magnetic stimulation, *aPRP* autologous platelet-rich plasma  
 \*Statistically significant changes displayed as bold

applications. It is a safe, non-invasive, and easy-to-use treatment without any adverse effects. The coils that yield electromagnetic fields are mounted in the helmet without any points touching the head skin or face. The electromagnetic field at the tissue level is significantly below the safety limit specified by the World Health Organization [33, 34].

Deep retinal capillary density has become a reliable and important follow-up parameter with improved image resolution, software, and artifact-removal programs in OCTA devices. We preferred to use the DRCD percentage together with visual acuity measurement with ETDRS logMAR chart for the assessment of the treatment efficacy over control groups in this trial.



**Fig. 3** Patient did not receive any ocular therapy, and only a systemic disorder was treated. Hyper-reflective bandlike zone persisted during the follow-up (arrows). There was no

any improvement in DRCD and BCVA (Table 3—Patient 4, DRCD 50.6% to 43.1%/BCVA 100 to 100 ETDRS letters)

Because these are the most reliable and sensitive methods for comparing follow-up parameters [21, 50].

Here, BCVA could be significantly increased with combined therapy of rEMS and aPRP in group 2 versus only application of rEMS in group 1. The PDGF $\beta$ /PDGFR $\beta$  pathway is critically important for the expansion of the pericyte migration along growing vessels, and various signaling pathways are also involved in angiogenesis [23–25]. In our study, the percentage of DRCDs increased significantly after the treatment modalities in groups 1 and 2. After stimulating these pathways and increasing the various growth factors in the microenvironment by just rEMS or combined with aPRP. However, significant improvement in BCVA could be achieved only with combined treatment (rEMS + aPRP). Regarding the efficacy of the treatment modalities (only rEMS versus rEMS + aPRP) on the BCVA and vessel density of DCP, the combined treatment approach was

significantly superior to treatment with only rEMS. There was no significant improvement in DRCD and BCVA in patients who had no intervention. In this group, only the systemic treatments for the underlying cause were initiated by the relevant experts. During this study, we did not encounter any adverse effects, patient complaint, or discomfort with noise or heating.

This prospective preliminary clinical trial has several limitations. The control group of the study comprised the patients with various BCVA who refused to receive either rEMS or aPRP therapies. Since DRCI is a recently described entity, it was difficult to establish a more homogenous control group. We did not differentiate between type 1 and type 2 deep retinal capillary ischemia; both types were included. The follow-up period was 1 month; therefore, other studies are needed to investigate the long-term results and establish the optimal treatment protocol. In cases with cataract and/or other

optic media opacities, the measurement of the vessel density in DCP might be affected leading to an inaccurate result. We did not study the visual field involvement and its changes with the treatment modalities because it was not possible to show the visual field changes for comparison in every case. We could not evaluate the different treatment parameters of the new Magnovision device; these are subject to another trial.

## CONCLUSION

Improved diagnosis of deep retinal capillary plexus ischemia can be achieved by considering the presence of acute-onset visual symptoms without visible fundus changes as well as hyper-reflective bands around the OPL. With systemic checkup, it is possible to detect the serious systemic diseases that may cause vital events. In mild cases, only rEMS (which is non-invasive and easy-to-use) might have beneficial effects on deep retinal capillary density. In more severe cases, sub-tenon fresh aPRP injection together with rEMS may be more effective in the treatment of local ischemia of the retina in order to augment the response and prevent permanent retinal damage and scotomas.

## ACKNOWLEDGEMENTS

We thank the participants of the study.

**Funding.** No funding or sponsorship was received for this study and the Rapid Service Fees were funded by the Ankara University Tecnopolis Institute. All authors had full access to all of the data in this study and take complete responsibility for the integrity of the data and accuracy of the data analysis.

**Authorship.** All named authors meet the International Committee of Medical Journal Editors (ICMJE) criteria for authorship for this article, take responsibility for the integrity of the work as a whole, and have given their approval for this version to be published.

**Medical Writing Assistance.** Medical writing and editorial assistance was provided by Ali Hariri from the American Manuscript Editors Company, which was funded by the authors.

**Compliance with Ethics Guidelines.** Ethics committee approval for the transcranial electromagnetic stimulation study was obtained from the Ankara University Faculty of Medicine Clinical Research Ethics Committee (17-1177-18) as well as and Review Board of the Drug and Medical Device Department within the Turkish Ministry of Health (2018-136). These committees had already approved the aPRP work (12-595-16 and 16-AKD-30). The study was performed in accordance with the tenets of the 1964 Declaration of Helsinki. Written informed consent was obtained from the patients prior to enrollment.

**Disclosures.** Emin Özmert and Umut Arslan have nothing to declare.

**Data Availability.** The datasets generated during and/or analysed during the study are available from the corresponding author on reasonable request.

## REFERENCES

1. Campbell JP, Zhang M, Hwang TS, et al. Detailed vascular anatomy of the human retina by projection-resolved optical coherence tomography angiography. *Scientific Rep.* 2017. <https://doi.org/10.1038/srep42201>.
2. Tan PEZ, Yu PK, Balaratnasingam C, et al. Quantitative confocal imaging of the retinal microvasculature in the human retina. *Investig Ophthalmol Vis Sci.* 2012;53(9):5728. <https://doi.org/10.1167/iov.12-10017>.
3. Park JJ, Soetikno BT, Fawzi AA. Characterization of the middle capillary plexus using optical coherence tomography angiography in healthy and diabetic eyes. *Retina.* 2016;36:2039–50.
4. Linsenmeier RA, Zhang HF. Retinal oxygen: from animals to humans. *Prog Retin Eye Res.* 2017;58:115–51.



5. Rahimy E, Sarraf D. Paracentral acute middle maculopathy: spectral domain optical coherence tomography feature of deep capillary ischemia. *Curr Opin Ophthalmol*. 2014;25:207.
6. Sarraf D, Rahimy E, Fawzi AA, et al. Paracentral acute middle maculopathy. *JAMA Ophthalmol*. 2013;131(10):1275. <https://doi.org/10.1001/jamaophthalmol.2013.4056>.
7. Niyousha MR, Hassanpoor N, Eftekhari A, Mousvi F. Simultaneous paracentral acute middle maculopathy and Purtscher-like retinopathy after acute febrile illness. *Can J Ophthalmol*. 2018;53(5):e184–6. <https://doi.org/10.1016/j.cjco.2017.11.020>.
8. Nemiroff J, Phasukkijwatana N, Sarraf D. Optical coherence tomography angiography of deep capillary ischemia. *Dev Ophthalmol*. 2016;56:139–45.
9. Kulikov AN, Maltsev DS, Leongardt TA. Retinal microvasculature alteration in paracentral acute middle maculopathy and acute macular neuroretinopathy. *Retin Cases Br Rep*. 2018. <https://doi.org/10.1097/icb.0000000000000709>.
10. Nakashima H, Iwama Y, Tanioka K, Emi K. Paracentral acute middle maculopathy following vitrectomy for proliferative diabetic retinopathy. *Ophthalmology*. 2018. <https://doi.org/10.1016/j.ophtha.2018.07.006>.
11. McLeod D. En face optical coherence tomography analysis to assess the spectrum of perivenular ischemia and paracentral acute middle maculopathy in retinal vein occlusion. *Am J Ophthalmol*. 2017;182:203–4.
12. Rahimy E, Kuehlewein L, Sadda SR, Sarraf D. Paracentral acute middle maculopathy. *Retina*. 2015;35:1921–30.
13. Nemiroff J, Kuehlewein L, Rahimy E, et al. Assessing deep retinal capillary ischemia in paracentral acute middle maculopathy by optical coherence tomography angiography. *Am J Ophthalmol*. 2016;162:121–32.
14. Bhavsar KV, Lin S, Rahimy E, et al. Acute macular neuroretinopathy: a comprehensive review of the literature. *Surv Ophthalmol*. 2016;61(5):538–65. <https://doi.org/10.1016/j.survophthal.2016.03.003>.
15. Introini U, Casalino G, Querques G, Bagini M, Bandello F. Acute macular neuroretinopathy following intranasal use of cocaine. *Acta Ophthalmol*. 2015;93(3):e239–40.
16. Munk MR, Jampol LM, Cunha Souza E, et al. New associations of classic acute macular neuroretinopathy. *Br J Ophthalmol*. 2015;100(3):389–94. <https://doi.org/10.1136/bjophthalmol-2015-306845>.
17. Li M, Zhang X, Ji Y, Ye B, Wen F. Acute macular neuroretinopathy in dengue fever: short-term prospectively followed up case series. *JAMA Ophthalmol*. 2015;133(11):1329–33.
18. Koenekeop RK. Why some photoreceptors die while others remain dormant: lessons from RPE65 and LRAT associated retinal dystrophies. *Ophthalmic Genet*. 2011;32(2):126–8.
19. Wang W, Lee SJ, Scott PA, et al. Two-step reactivation of dormant cones in retinitis pigmentosa. *Cell Rep*. 2016;15(2):372–85.
20. Sabharwala J, Seilheimer RL, Taoc X, Cowanc CS, Frankfortb BJ, Wub SM. Elevated IOP alters the space/time profiles in the center and surround of both ON and OFF RGCs in mouse. *PNAS*. 2017;114(33):8859–64.
21. Lavia C, Bonnin S, Maule M, Erginay A, Tadayoni R, Gaudric A. Vessel density of superficial, intermediate, and deep capillary plexuses using optical coherence tomography angiography. *Retina*. 2019;39(2):247–58. <https://doi.org/10.1097/iae.0000000000000241>.
22. Notodihardjo SC, Morimoto N, Kakudo N, et al. Comparison of the efficacy of cryopreserved human platelet lysate and refrigerated lyophilized human platelet lysate for wound healing. *Regen Ther*. 2019;10:1–9. <https://doi.org/10.1016/j.reth.2018.10.003>.
23. Zahn J, Loibl M, Sprecher C, et al. Platelet-rich plasma as an autologous and proangiogenic cell delivery system. *Mediat Inflamm*. 2017;2017:1–14. <https://doi.org/10.1155/2017/1075975>.
24. Armulik A. Endothelial/pericyte interactions. *Circ Res*. 2005;97(6):512–23. <https://doi.org/10.1161/01.res.0000182903.16652.d7>.
25. Benjamin LE, Hemo I, Keshet E. A plasticity window for blood vessel remodelling is defined by pericyte coverage of the preformed endothelial network and is regulated by PDGF-B and VEGF. *Development*. 1998;125:1591–8.
26. Arslan U, Özmert E, Demirel S, Örnek F, Şermet F. Effects of subtenon-injected autologous platelet-rich plasma on visual functions in eyes with retinitis pigmentosa: preliminary clinical results. *Graefes Arch Clin Exp Ophthalmol*. 2018;256(5):893–908. <https://doi.org/10.1007/s00417-018-3953-5>.
27. Klomjai W, Katz R, Lackmy-Vallée A. Basic principles of transcranial magnetic stimulation (TMS) and

- repetitive TMS (rTMS). *Ann Phys Rehabil Med.* 2015;58(4):208–13. <https://doi.org/10.1016/j.rehab.2015.05.005>.
28. Zhang N, Xing M, Wang Y, Tao H, Cheng Y. Repetitive transcranial magnetic stimulation enhances spatial learning and synaptic plasticity via the VEGF and BDNF–NMDAR pathways in a rat model of vascular dementia. *Neuroscience.* 2015;311:284–91. <https://doi.org/10.1016/j.neuroscience.2015.10.038>.
29. Luo J, Zheng H, Zhang L, et al. High-frequency repetitive transcranial magnetic stimulation (rTMS) improves functional recovery by enhancing neurogenesis and activating BDNF/TrkB signaling in ischemic rats. *Int J Mol Sci.* 2017;18(2):455. <https://doi.org/10.3390/ijms18020455>.
30. Wang F, Zhang C, Hou S, Geng X. Synergistic effects of mesenchymal stem cell transplantation and repetitive transcranial magnetic stimulation on promoting autophagy and synaptic plasticity in vascular dementia. *J Gerontol Ser A.* 2018. <https://doi.org/10.1093/gerona/gly221>.
31. Webster K, Ro T. Retinal and visual cortex distance from transcranial magnetic stimulation of the vertex affects phosphene perception. *Exp Brain Res.* 2017;235(9):2857–66. <https://doi.org/10.1007/s00221-017-5022-4>.
32. Nikolaeva NV, Bolotova NV, Kamenskikh TG, Raigorodskii IuM, Kolbenev IO, Luk'ianov VF. Transcranial magnetotherapy for the correction of initial manifestations of diabetic retinopathy in children. *Vopr Kurortol Fizioter Lech Fiz Kult.* 2009;3:25–8.
33. Chandra T, Chavhan GB, Sze RW, et al. Practical considerations for establishing and maintaining a magnetic resonance imaging safety program in a pediatric practice. *Pediatr Radiol.* 2019;49(4):458–68. <https://doi.org/10.1007/s00247-019-04359-8>.
34. Heintz PH, Sandoval DJ, Chambers GD, Adolphi NL. Biological effects of magnetic resonance imaging. In: Kelsey CA, Heintz PH, Sandoval MS, et al., editors. *Radiation biology of medical imaging.* Hoboken: Wiley; 2018. p. 281–95.
35. Sridhar J, Shahlaee A, Rahimy E, et al. Optical coherence tomography angiography and en face optical coherence tomography features of paracentral acute middle maculopathy. *Am J Ophthalmol.* 2015;160(6):1259–1268.e2. <https://doi.org/10.1016/j.ajo.2015.09.016>.
36. Colafrancesco V, Coassin M, Rossi S, Aloe L. Effect of eye NGF administration on two animal models of retinal ganglion cells degeneration. *Ann Ist Super Sanita.* 2011;47:284–9.
37. Lambiasi A, Aloe L, Centofanti M, et al. Experimental and clinical evidence of neuroprotection by nerve growth factor eye drops: implications for glaucoma. *Proc Natl Acad Sci USA.* 2009;106:13469–74.
38. Lambiasi A, Mantelli F, Sacchetti M, Rossi S, Aloe L, Bonini S. Clinical applications of NGF in ocular diseases. *Arch Ital Biol.* 2011;149:283–92.
39. Mysona BA, Zhao J, Bollinger KE. Role of BDNF/TrkB pathway in the visual system: therapeutic implications for glaucoma. *Expert Rev Ophthalmol.* 2017;12(1):69–81.
40. Giannos SA, Kraft ER, Zhao ZY, Merkley KH, Cai J. Photokinetic drug delivery: near infrared (NIR) induced permeation enhancement of bevacizumab, ranibizumab and aflibercept through human sclera. *Pharm Res.* 2018;35(6):1. <https://doi.org/10.1007/s11095-018-2392-7>.
41. Demetriades AM, Deering T, Liu H, et al. Transscleral delivery of antiangiogenic proteins. *J Ocul Pharmacol Ther.* 2008;24(1):70–9. <https://doi.org/10.1089/jop.2007.0061>.
42. Meng T, Kulkarni V, Simmers R, Brar V, Xu Q. Therapeutic implications of nanomedicine for ocular drug delivery. *Drug Discov Today.* 2019. <https://doi.org/10.1016/j.drudis.2019.05.00>.
43. Li SK, Hao J. Transscleral passive and iontophoretic transport: theory and analysis. *Expert Opin Drug Deliv.* 2017;15(3):283–99. <https://doi.org/10.1080/17425247.2018.1406918>.
44. Joseph RR, Tan DWN, Ramon MRM, et al. Characterization of liposomal carriers for the trans-scleral transport of ranibizumab. *Scientific Rep.* 2017;7(1):1. <https://doi.org/10.1038/s41598-017-16791-7>.
45. Marg E. Magnetostimulation of vision: direct non-invasive stimulation of the retina and the visual brain. *Optom Vis Sci.* 1991;68(6):427–40.
46. Bagattini C, Mazzi C, Savazzi S. Waves of awareness for occipital and parietal phosphenes perception. *Neuropsychologia.* 2015;70:114–25. <https://doi.org/10.1016/j.neuropsychologia.2015.02>.
47. Kammer T, Beck S. Phosphene thresholds evoked by transcranial magnetic stimulation are insensitive to short-lasting variations in ambient light. *Exp Brain Res.* 2002;145(3):407–10. <https://doi.org/10.1007/s00221-002-1160-3>.



- 
48. Marzi CA, Mancini F, Savazzi S. Interhemispheric transfer of phosphenes generated by occipital versus parietal transcranial magnetic stimulation. *Exp Brain Res.* 2008;192(3):431–41. <https://doi.org/10.1007/s00221-008-1496-4>.
  49. Drakon AK, Elfimov MA, Illarionov VE, Ivanova II, Portnov VV. Contemporary potential of nonmedical treatment in ophthalmology. *Med Tr Prom Ekol.* 2016;2:6–11.
  50. Lim LA, Frost NA, Powell RJ, Hewson P. Comparison of the ETDRS logMAR, “compact reduced logMAR” and Snellen charts in routine clinical practice. *Eye (Lond).* 2010;24(4):673–7.